


**U.S. Copyright Law  
(title 17 of U.S. code)  
governs the reproduction  
and redistribution of  
copyrighted material.**

**Downloading this  
document for the  
purpose of  
redistribution is  
prohibited.**



**Michael S. Gazzaniga**

UNIVERSITY OF CALIFORNIA,  
SANTA BARBARA

**Richard B. Ivry**

UNIVERSITY OF CALIFORNIA,  
BERKELEY


**George R. Mangun**

UNIVERSITY OF CALIFORNIA,  
DAVIS


*With*

**Megan S. Steven**

DARTMOUTH COLLEGE




**COGNITIVE NEUROSCIENCE**  
**THE BIOLOGY OF THE MIND**



**THIRD EDITION**



W • W • NORTON & COMPANY  
NEW YORK • LONDON



Copyright © 2009, 2002, 1998 by Michael S. Gazzaniga, Richard B. Ivry, and George R. Mangun

All rights reserved.

PRINTED IN THE UNITED STATES OF AMERICA

---

*Editor: Jon W. Durbin.*  
*Senior project editor: Kim J. Yi.*  
*Senior production manager: Ben Reynolds.*  
*Copy editor: Stephanie Hiebert.*  
*Editorial assistants: Alexis Hiltz and Jason Spears.*  
*Book design: Jack Meserole and Rubina Yeh.*  
*Illustrations: Frank Forney and ElectraGraphics, Inc.*

---

*The text of this book is composed in Minion with the display set in Myriad.*  
*Composition: TSI Graphics.*  
*Manufacturing: R. R. Donnelley—Willard Division.*

---

Library of Congress Cataloging-in-Publication Data

Gazzaniga, Michael S.  
Cognitive neuroscience : the biology of the mind / Michael S.  
Gazzaniga, Richard B. Ivry, George R. Mangun ; with Megan S. Steven.  
—3rd ed.  
p. ; cm.  
Includes bibliographical references and index.  
**ISBN 978-0-393-92795-5** (hardcover)  
1. Cognitive neuroscience. I. Ivry, Richard B. II. Mangun, G. R.  
(George Ronald), 1956— III. Title.  
[DNLM: 1. Brain—physiology. 2. Cognition—physiology. 3. Cognitive  
Science. 4. Neuropsychology. WL 300 G291c2009]  
QP360.5.G39 2009  
612.8'233—dc22

2008016822

W. W. Norton & Company, Inc., 500 Fifth Avenue, New York, NY 10110  
[www.wwnorton.com](http://www.wwnorton.com)

W. W. Norton & Company Ltd., Castle House, 75/76 Wells Street, London W1T 3QT

# 3

## Neuroanatomy and Development

The relationship between brain anatomy and cognition has been the source of fascination and puzzlement for hundreds of years. For example, many studies have attempted to relate aspects of brain organization to intelligence in humans. Consider the story of one of the greatest brains in human history, that of Albert Einstein. Einstein was clearly a person of exceptional ability. During his life he mentally tiptoed among atoms and stars and brought his incredible insights about the physics of the universe to humankind in the form of concrete mathematical descriptions. In a letter to his colleague Jacques Hadamard, Einstein said of his own scientific thinking that “words do not seem to play any role,” yet there is an “associative play” involving “more or less clear images” of a “visual and muscular type” (Hadamard, 1945, p. ix).

Numerous efforts have been made to identify unique anatomical features of Einstein’s brain that might explain his genius. When Einstein died in 1955 at the age of 76, his brain was extracted and saved. It was weighed, perfused with a solution of the chemical preservative formalin, measured, and photographed. The brain was then sectioned and embedded in a material that permitted it to be thinly sliced to make histological slides for microscopic analysis. These specimens and materials documenting their original three-dimensional relationships in the whole brain were stored for future scientific study. Sandra Witelson and her colleagues at McMaster University in Canada performed one such study (Witelson et al., 1999). They investigated the dimensions and gyral morphology of Einstein’s brain, comparing the original measurements to their own new measurements of the brain and to measurements calculated from the original calibrated photographs taken shortly after his death.

The characteristics of Einstein’s brain were compared to those of brains from a few dozen normal per-

sons that had been donated for scientific research. These researchers found two prominent features of Einstein’s brain that were very different from the normal control group of brains. The first observation was that the **Sylvian fissure**, the division that separates the temporal lobe from the frontal and parietal lobes, in Einstein’s brain had an unusual anatomical organization (see the description of gross anatomy later in the chapter to appreciate the anatomical features described here). Unlike the control brains, Einstein’s brain showed a strange confluence of the Sylvian fissure with the central sulcus on the brain’s lateral surface; most brains have a Sylvian fissure that projects posteriorly to end in an area surrounded by the supramarginal gyrus. The second unusual feature resulted from this anatomy: Einstein’s inferior parietal lobe was actually larger, and indeed thicker (15%) in lateral to medial extent.

Witelson and her colleagues hypothesized that the increased size of Einstein’s inferior parietal cortex might have been related to his intellectual capacity, although they pointed out that it is difficult to make any

conclusions about causal relationships from their data. Nonetheless, it is remarkable that they found gross anatomical features that were so strikingly different in Einstein's brain in comparison to the brains of the rest of us, who for the most part are merely trying to understand what Einstein said, never mind attempting to generate new insights ourselves. From such investigations, hypotheses can be generated and then tested in brains removed at autopsy or, in the modern age of neuroimaging, in brains in the living human. Perhaps the next Einstein, like the last one, who permitted electroencephalograms to be recorded from electrodes on his head, will lie inside a scanner so that young cognitive neuroscientists can measure his or her living, thinking brain and its function.

Form is derived from function. This is a central tenet in biology. Throughout the history of neuroscience, researchers have probed the organization of the nervous system, hoping that, by doing so, they would unlock its secrets. In Chapter 1 we saw how the great neuroanatomists Santiago Ramón y Cajal of Spain and Camillo Golgi of Italy used information from cellular neuroanatomy to argue for different theories of information processing in the nervous system. This work continues to the present, with a march toward new and higher-resolution techniques for probing the biological foundations of the mind.

In the next chapter we will learn about some of these new techniques for revealing the functional anatomy of the brain—techniques that are based on understanding

the relationships between form and function. In later chapters we will see many examples of the anatomical correlates of different aspects of cognition. It will become clear that gross anatomy must be interpreted in light of the functional interactions of structures, circuits, and systems in the nervous system because similar structures may perform very different computations, and the same structure may participate in different functions at different times. Understanding how the form of the nervous system supports the myriad functions of the mind is one of the major challenges of cognitive neuroscience.

In this chapter we review the gross anatomy and microanatomy of the brain and nervous system. We describe the major anatomical structures of the brain and make note of the vasculature and ventricular systems. We discuss how the brain develops prenatally and how it changes even in adulthood. Some discussion of the functional organization of the mental functions that the brain supports begins here; subsequent chapters will describe in more detail the many functions of the human brain in perception and cognition. Hence, the aim of this chapter is to provide a reference for the material to be covered later, and to introduce the neuroanatomical and neurodevelopmental terms that will be important throughout the book. Refer back to the content of this chapter and Chapter 2 as needed to interpret the complexities of the form and function of the nervous system that are introduced later.

## NEUROANATOMY

*Neuroanatomy* is the study of the nervous system's structure. It is concerned with identifying the parts of the nervous system and describing how the parts are connected. As with all of anatomy, descriptions can be made at many levels. For the neuroanatomist, investigations occur at one of two levels: *gross neuroanatomy*, which focuses on general structures and connections visible to the naked eye, and *fine neuroanatomy* (also referred to as *microscopic anatomy*), in which the main task is to describe the organization of neurons and their connections and subcellular structure. In Chapter 2, to provide the background necessary to consider the physiology of the nervous system in signaling, we introduced cellular neuroanatomy. (Refer back to the first part of Chapter 2 for an overview of cells of the nervous system.) Here we begin with a short description of the methods that help reveal the gross, microscopic, and functional neuroanatomy of the nervous system, the latter being the

anatomical organization of cells, circuits, and systems that support a particular function, such as object perception.

### Methods in Neuroanatomy

Different approaches are used to investigate the nervous system at different levels of description, and indeed, these methods are highly specialized such that they represent different subdisciplines of neuroanatomy. Their development follows roughly the historical story laid out in Chapter 1, for the field of neuroanatomy developed in step with the development of new techniques.

### GROSS DISSECTION

For identification of gross anatomy, the first challenge is to figure out how to view the brain. Until recently, when neuroimaging made it possible to view the living brain

within the heads of animals and humans in vivo (see Chapter 4), the only available approach was the tried-and-true method of removing the brain from the head and putting it on the table, or more accurately, in a container filled with a preservative such as formalin. A neuroanatomist undertaking this procedure immediately is made aware of the specialized defenses that protect the brain. Not only is the brain enclosed within the skull's protective bony structure, but also it is surrounded by the **dura mater**, which consists of dense layers of collagenous fibers (*dura* is Latin for “hard” or “tough,” and *mater* is Latin for “mother”).

After the dura mater is removed, superficial examination reveals many prominent structures (Figure 3.1). The **gyri** (singular *gyrus*; the protruding rounded surfaces) and primary **sulci** (singular *sulcus*; the numerous smaller invaginations seen as creases) and *fissures* (the less numerous, larger invaginations) of the cerebrum; the gradual narrowing of the brainstem; and the elaborate folding of the cerebellar cortex can be identified without the aid of a microscope. Further dissections expose internal structures and reveal organizational principles. For example, slicing through the brain reveals the dichotomy of **gray matter** and **white matter**: The gray matter forms a continuous cortical sheath enshrouding a seemingly homogeneous mass of white matter. Gray matter is so named because it appears darker and even a bit grayish in preserved brains, although it is more typically pinkish to reddish in the living brain, owing to its vascularization. The gray matter contains cell bodies of neurons and glial cells. The white matter is so termed

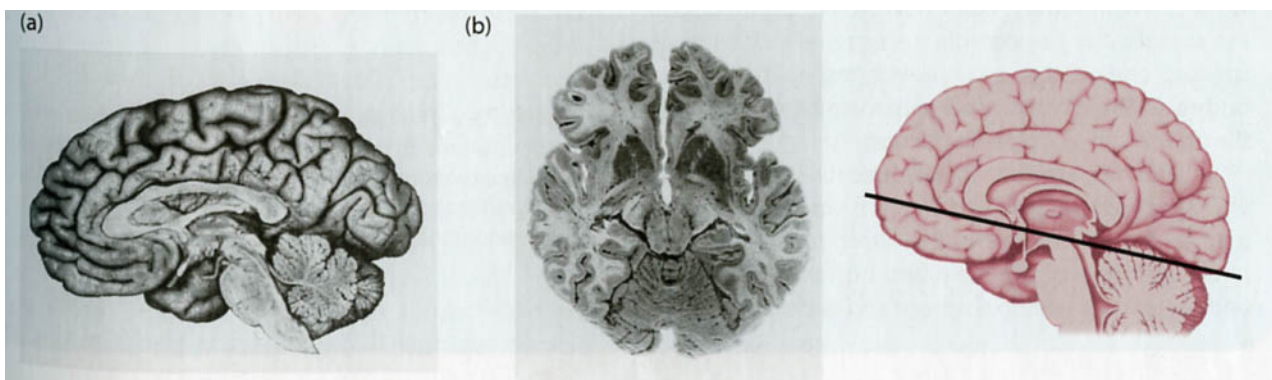
because it looks lighter than the gray matter in preserved tissues; it actually appears quite milky white in the living brain. This coloring is due to the fatty myelin surrounding the axons (see Chapter 2).

Neuroanatomical dissection of the brain can provide a relatively detailed description of the organization of the major systems, structures, and connections of the brain. For example, gross dissection will reveal the inputs to and outputs from peripheral sensory structures or motor effectors (muscles), via nerve bundles. It is also possible to follow the trajectory of axons grouped in large fiber **tracts** (bundles of axons) as they course through the brain and connect with different regions. Such dissection will show the geniculostriate projections from the thalamus to the visual cortex that we touch upon later in this chapter and will learn about in detail in Chapter 5. In another good example, dissection will reveal the arcuate fasciculus, a prominent fiber tract interconnecting Broca's and Wernicke's areas in support of language functions (see Chapter 10). These interconnections observable at the gross level are revealed in greater detail with tract-tracing methods using chemical substances in animals and degeneration and neuroimaging methods in animals and humans. Some of these methods are reviewed in the next section.

### MICROANATOMY AND HISTOLOGY: CELL STAINING AND TRACT TRACING

If we simply looked at the brain in gross dissections, we would not know that structures such as the white matter

**Figure 3.1** (a) Midsagittal section through the human cerebral cortex. This medial view of the right hemisphere of a postmortem brain reveals prominent features of the gross anatomy, including cortical, subcortical, cerebellar, and brainstem regions. The frontal pole is on the left. On the surface of the cortex (top portions mostly), the crowns of the various cortical gyri can be seen; the folded regions of the cortex (the sulci) appear as lines or creases. (b) A horizontal (also called *axial*) section through the human brain at approximately the level diagrammed in the drawing at right (dark line). The left and right cerebral hemispheres (frontal pole now at the top), the underlying subcortical structures, and portions of the cerebellum (bottom) can be seen in the horizontal section. The gray matter (darker regions) and white matter (lighter regions) are clearly visible.





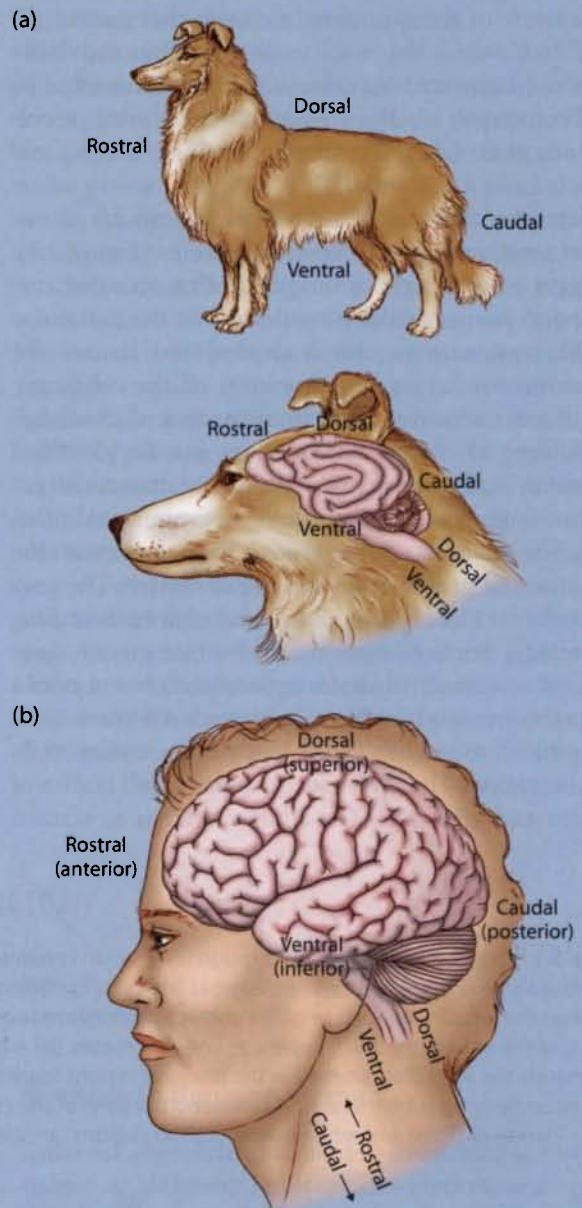
## THE COGNITIVE NEUROSCIENTIST'S TOOLKIT

## Navigating in the Brain

Because the brain is a complex three-dimensional object with numerous structures and pathways that are difficult to imagine in two-dimensional pictures, it is important to utilize conventions for describing the relations of regions. In general, the terms we use were derived from those used by anatomists to describe similar relations in the body as a whole; therefore, the brain's orientation with respect to the body determines the coordinate frame of reference that is used to describe anatomical relationships in the brain. But some confusing aspects of the terminology arise from differences in how the head and body are arranged in animals that walk on four legs versus humans, who are upright. Consider a dog's body surfaces. The front end is the *rostral* end, meaning "nose." The opposite end is the *caudal* end, the "tail." The back is the *dorsal* surface and the bottom surface is the *ventral* surface (**a, top**). We can refer to the dog's nervous system by using the same coordinates (**a, bottom**). The part of the brain toward the front is the rostral end, toward the frontal lobes; the posterior end is the caudal end, toward the occipital lobe; and the top and bottom are, respectively, the dorsal and ventral surfaces of the brain. This seems to be a reasonable set of conventions, or is it? Consider the human (**b**).

Humans are atypical and thus create confusing problems with respect to anatomical nomenclature. The reason is simple: Humans stand upright and therefore tilt their heads down in order to be parallel with the ground. Thus, the dorsal surface of the body and brain are now at right angles to each other. But the conventions still apply, though there may be some confusion unless we remember that humans have tilted their heads. *Rostral* still means "toward the frontal pole," and *caudal* still means "toward the occipital pole," as long as we are referring to the brain; however, when we discuss the spinal cord, the coordinate systems shift with respect to one another but not with respect to the local body axis. Thus, in the spinal cord *rostral* means "toward the brain," just as it does in the dog.

In humans, perhaps in part because of the differences in posture between humans and quadrupedal animals, we also use terms like *superior* and *inferior* to refer to the top of the brain and bottom, and *anterior* and *posterior* to refer to the front and back, respectively.



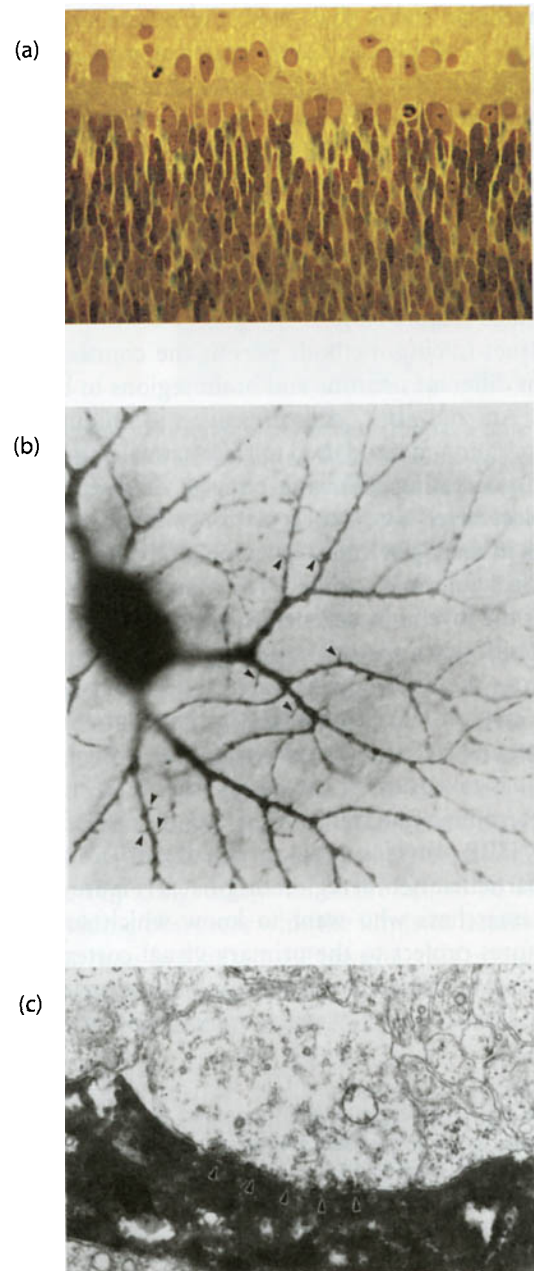
Anatomical terms for describing various views of anatomy and sections through brain and body. The relationship between a bipedal human and quadrupedal animal leads to some important considerations in describing the surfaces of the brain and spinal cord.

are neural elements rather than supportive tissues. To make this inference, neuroanatomists must probe for finer detail with high-power microscopes. For example, microscopic examination reveals that the white matter is actually composed of millions of individual fibers, each surrounded by myelin. This level of analysis is the domain of the histologist. *Histology* is the study of tissue structure through microscopic techniques like those introduced in Chapter 1 in the work of the early neuroanatomists Ramón y Cajal, Golgi, and Purkinje.

A primary concern for neuroanatomists is to identify the patterns of connectivity in the nervous system in order to lay out the neural “highways” that allow information to get from one place to another. This problem is made complex by the fact that neurons are not wired together in a simple, serial circuit. A single cortical neuron is likely to be innervated by (i.e., receive inputs from) large numbers of neurons, and the axons from these input neurons can originate in widely distributed regions. That is, there is tremendous convergence in the nervous system, as well as divergence, in which a single neuron can receive inputs from many neurons and/or project to multiple target neurons in different regions.

Most axons are short projections from neighboring cortical cells. Others can be quite long, originating in more distant cortical regions and reaching their target only after descending below the cortical sheath into the white matter, traveling through long fiber tracts, and then entering another region of cortex, subcortical **nucleus**, or spinal layer to synapse on another neuron. Neighboring and distant connections between two cortical regions are referred to as *corticocortical connections*, following the convention that the first part of the term identifies the source and the second part identifies the target. Inputs that originate in subcortical structures such as the thalamus would be referred to as *thalamocortical connections*; the reverse are *corticothalamic*, or more generally, *corticofugal projections* (projections from more central structures like cortex, outward toward the periphery).

Much of the progress in neuroanatomy has been prompted by the development and refinement of new *stains*, chemicals of various sorts that are selectively absorbed by specific neural elements (see Chapter 1). Staining methods were discovered by trial and error or by intention, such as when the interaction of a chemical with tissues yielded an interesting pattern of staining that then became useful. Cell staining allows different levels of analysis. For example, we can stain pieces of neural tissue to reveal the laminar organization of the retina (Figure 3.2a), or we can zoom in on individual cells that have either taken up or been injected with



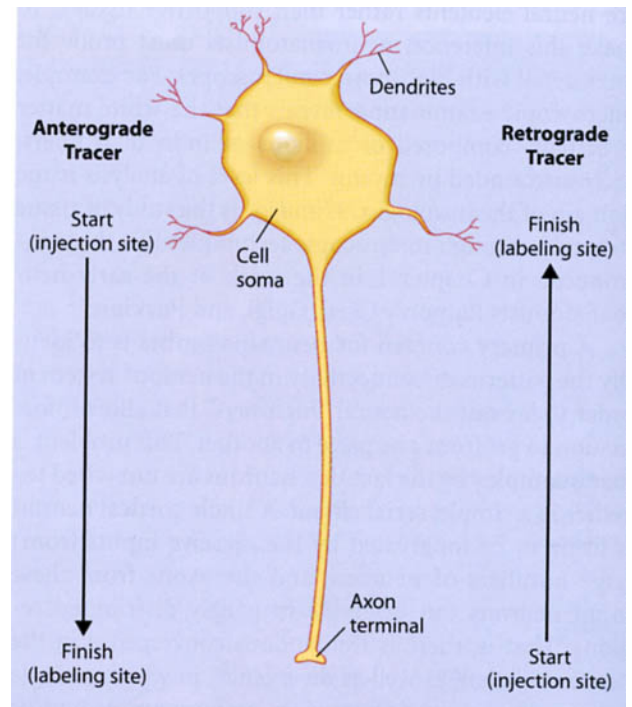
**Figure 3.2** Neuroanatomical analysis at different scales. **(a)** Cells from the retina of a young ferret, stained and magnified by a light microscope. This section of the retina spans approximately 1.5 mm. **(b)** A ganglion cell from the cat retina that has been injected with stain to highlight its dendritic arborization. The magnification by light microscopy here is much greater than in (a). The arrowheads highlight places where short dendritic extensions, or spines, are visible. Processes along one dendritic branch can be visualized with the electron microscope. **(c)** The dark region of this electron micrograph is one of the stained dendrites of the cell shown in (b). The light regions are axons forming synapses along the dendrite. At this magnification, it is possible to see the synaptic vesicles (arrowheads) in the axon terminals. These vesicles contain neurotransmitter as described in Chapter 2.



intracellular stains that show the neural architecture (Figure 3.2b). We can examine such stained cells with a light microscope. At a higher level of resolution, we can examine subcellular organelles such as synaptic vesicles inside an axon terminal with an electron microscope, which, as the name suggests, uses a beam of electrons rather than light to “illuminate” neural tissues (Figure 3.2c). Another approach is to use fluorescent stains and ultraviolet light to visualize the structures that take up the stains (Figure 3.3).

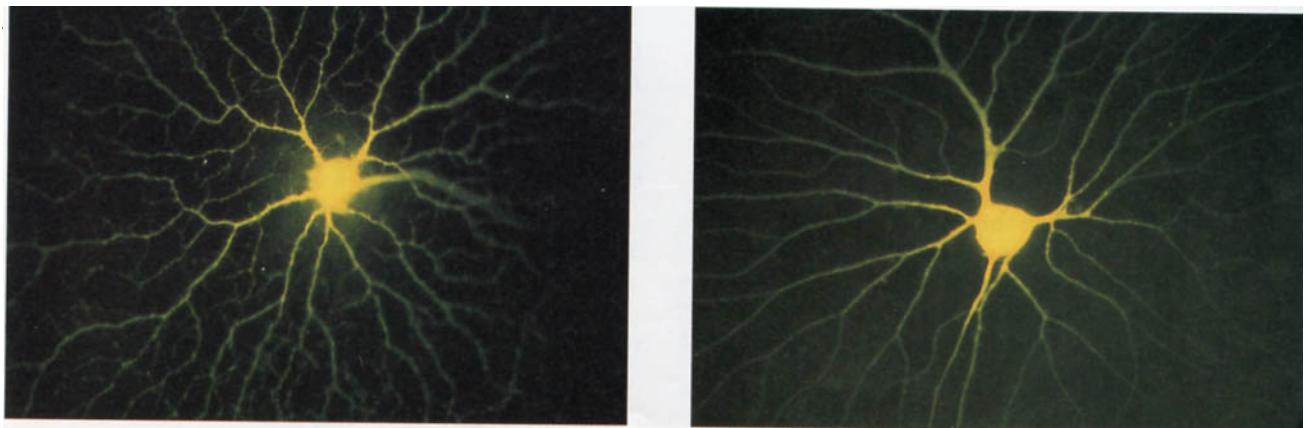
Tract-tracing methods permit the connections between different neurons and brain regions to be identified. An old, but still effective, technique is the degeneration method used to trace axonal pathways that are degenerating following damage or disease. At the simplest level, one can look for missing myelinated axons in damaged brains. At a more advanced level, the Marchi stain can be applied. The Marchi stain selectively stains the myelin in degenerating axons—a process that can result when the cell bodies die or the axons are cut off from the cell body. A more modern but now common method makes use of the enzyme *horseradish peroxidase* (HRP). HRP is a *retrograde* tracer (Figure 3.4) in that it is taken up by the axons when it is injected at axon terminals and transported back to their cell bodies. Thus, HRP provides a tool to visualize where the input to a particular neural region originates (Figure 3.5).

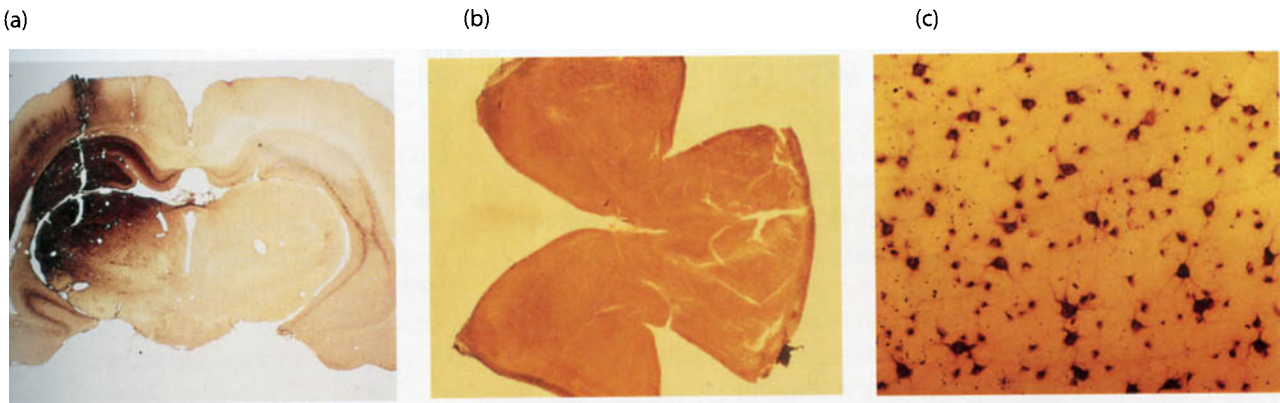
Researchers who want to know which subcortical structures project to the primary visual cortex can use HRP as a retrograde transport tool, injecting it into the input layers of the visual cortex. HRP is absorbed



**Figure 3.4** Directionality of anterograde and retrograde tracers. Anterograde tracers (**left**) are injected near and taken up by the cell soma. They then travel along the axon and label it with a tracer. Retrograde tracers (**right**) are injected near the axon terminal and are taken up there. They travel up the axon, where they terminate and label the cell soma.

**Figure 3.3** Fluorescent staining method. **(a)** The soma and dendritic arbor of a retinal neuron in the prenatal cat, 8 days before birth. **(b)** The soma and dendritic arbor of a neuron from this same structure in the adult cat. Many dendritic branches are eliminated during development, and staining permits this developmental change to be visualized and quantified. Fluorescent stains come in a variety of types and may include adding a fluorescent molecule to an antibody or other molecule that binds with material in a neuron, or injecting a fluorescent material into a neuron and allowing it to diffuse throughout the cell.





**Figure 3.5** Staining techniques reveal connections between distant neural structures. Horseradish peroxidase (HRP) is a commonly used tracer. When used as a retrograde label, HRP is taken up by axon terminals and is transported back to the cell bodies. The animal is then killed, and histological methods are used to identify the location of the stain. **(a)** Injection site in the lateral geniculate nucleus of the thalamus of a rat. **(b)** A flattened retina, shown under very low-level magnification. **(c)** Individual neurons (the black spots are cell bodies of neurons filled with stain) under high magnification. If you look closely, you can see the shapes of many of these neurons and their dendrites.

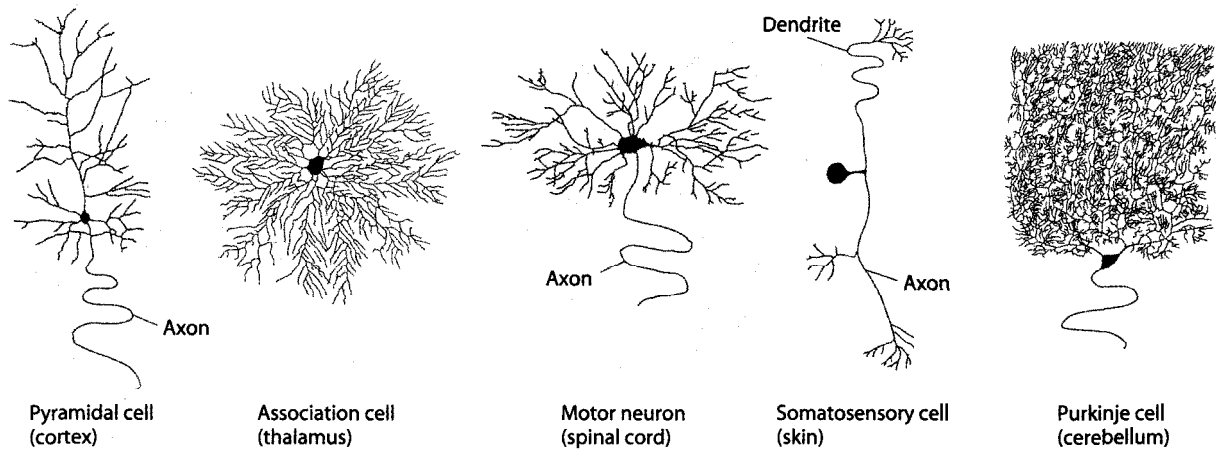
through the same axonal channels that allow neural transduction via the inflow and outflow of sodium, potassium, and calcium ions. Once inside, the HRP diffuses up the axon to the cell body. The animal is then sacrificed and its brain removed. The HRP-injected tissue can then be treated with chemicals that turn the HRP a variety of colors from black to blue or brown. Examining thin slices of brain tissue cut with a sharp mechanical knife called a *microtome*, researchers can identify regions containing cell bodies labeled by HRP.

HRP is just one of many retrograde tracers. Other chemicals serve as *anterograde* tracers (see Figure 3.4), in that they are absorbed at the dendrites or soma and then diffuse along the axons. One popular approach is to use radioactively labeled materials as tracers—for example, radiolabeled amino acids. Autoradiography then can be used to visualize the pattern of staining. In this technique, tissue is sliced, labeled, and placed on a photographic material to let the radioactivity expose the photographic emulsion, producing a picture of the distribution of label in the tissue. In combination, retrograde and anterograde tracers allow researchers to identify the inputs to a specific region and determine where the axons from a particular region terminate. In this manner, the neuroanatomist can construct projection maps of the patterns of connectivity for small and large circuits of the nervous system.

Neuroanatomists have used histological techniques to classify neurons into groups based on their morphology (form). Upon close examination, it is clear that, despite the commonalities across neurons (most have cell bodies, axons, and dendrites), they are very heterogeneous, varying in size and shape. For some

neurons, such as the giant pyramidal cells in the cerebral cortex, the dendritic arbor is relatively small. In contrast, the Purkinje cells of the cerebellar cortex have vast dendritic arbors, allowing for more than 200,000 synaptic input contacts (Figure 3.6; see also Chapter 2).

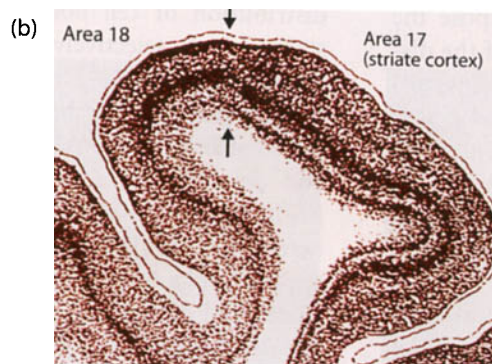
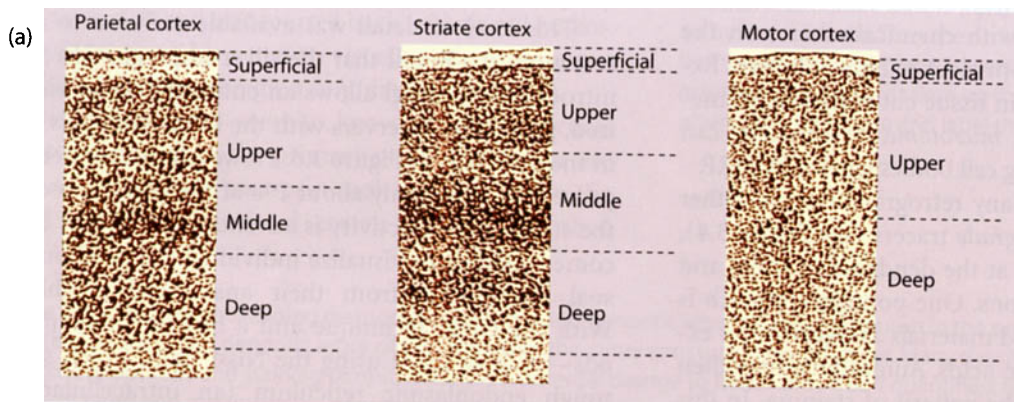
This level of detail was available early on to neuroanatomists. Recall that the silver impregnation stain introduced by Golgi allows an entire cell to be visualized, providing observers with the kinds of details seen in the drawings in Figure 3.6. However, this mysterious procedure stains only about 1% of the cells exposed to the stain. Such selectivity is advantageous in that it becomes possible to visualize individual cells without visual interference from their anatomical neighbors. With the Golgi technique and a host of other methods—such as those using the Nissl stain, which stains rough endoplasmic reticulum (an intracellular organelle, also referred to as *Nissl substance*), revealing the distribution of cell bodies (somata), or the Weigert stain, which selectively stains myelin, revealing the axons of neurons—a researcher can (painstakingly) catalog the cellular architecture and layering patterns of different brain regions. Indeed, as noted in Chapter 1 and described in more detail later in this chapter, Korbinian Brodmann used this technique to devise his **cytoarchitectonic map** of the brain. He methodically applied stains to samples from the entire surface of the cortex and obtained a picture of regional variations in cellular architecture. Brodmann partitioned cortical areas according to these differences in cell morphology, density, and layering (Figure 3.7) and introduced a numbering scheme that continues to be widely employed in the neurosciences today.



**Figure 3.6** Five different neurons in the central and peripheral nervous systems. These neurons vary greatly in size (they are not drawn to scale); for example, the axon of an association cell in the thalamus may extend less than 1 mm, whereas the axon of the pyramidal cell may traverse the length of the spinal cord

The methods that we have described here and others related to these general neuroanatomical approaches have been used to investigate and describe how the nervous

system is organized. Now let's turn to an overview of the organization of the human brain and nervous system.



**Figure 3.7** The gray matter of the cerebral cortex is composed of unmyelinated cell bodies that give a layered appearance as a function of the different cell types and their groupings in cross-sectional views (cortical surface at top). **(a)** As shown in these examples from the macaque monkey, across different cortical areas the density and layering of the cell types vary. Brodmann used these variations in density and layering, as well as neuronal morphology to define the boundaries between different cortical areas. **(b)** This example shows a cross section through the visual cortex. The arrows identify the border between two cytoarchitecturally defined Brodmann's areas. Note the change in the pattern of layering.



## GROSS AND FUNCTIONAL ANATOMY OF THE NERVOUS SYSTEM

Signaling in the nervous system occurs along well-defined pathways, and via specific anatomical relays to circumscribed areas of the brain, spinal cord, and peripheral musculature. A review of the nervous system's anatomical organization clarifies this organization. We begin with a global view; in later chapters we'll focus on specific anatomical and physiological systems relevant to specific sensory, cognitive, and motor processes.

The nervous system has two major subdivisions: the **central nervous system (CNS)** consisting of the brain and spinal cord, and the **peripheral nervous system (PNS)**, consisting of everything outside the CNS. The CNS can be thought of as the command-and-control portion of the nervous system. The PNS represents a courier network that delivers sensory information to the CNS and carries the motor commands of the CNS to the muscles, to control the voluntary muscles of the body (somatic motor system) and the involuntary activity of the smooth muscles, heart, and glands (autonomic motor system). In most of the remainder of this chapter, we focus on describing the CNS, to lay the groundwork for the studies of cognition that follow.

### Cerebral Cortex

The **cerebral cortex** has two symmetrical hemispheres that consist of large sheets of (mostly) layered neurons. It sits over the top of core structures, including parts of the limbic system and basal ganglia, and surrounds the structures of the diencephalon, all of which will be considered later. Together, the cerebral cortex, basal ganglia, and diencephalon form the forebrain. The term *cortex* means “bark,” as in tree bark, and in higher mammals and humans it contains many infoldings, or convolutions (Figure 3.8). As noted earlier, the infoldings of the cortical sheet are further defined as sulci (the folded regions) and gyri (the crowns of the folded tissue that one observes when viewing the surface). Many mammalian species, such as the rat or even New World monkeys like the owl monkey, have smoother, less folded cortices with few sulci and gyri.

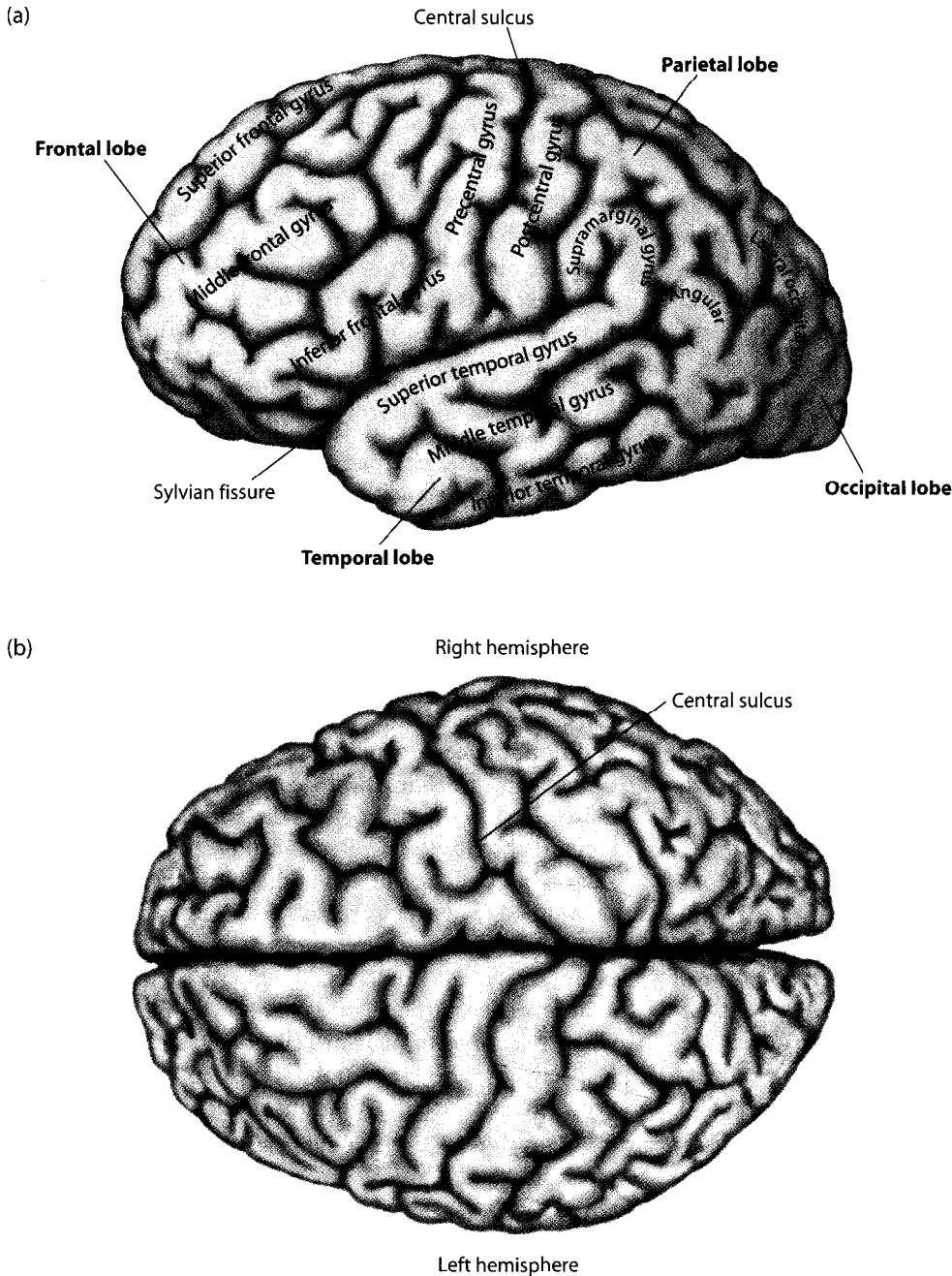
The folds of the human cortex serve a functional purpose: to pack more cortical surface into the skull. If the human cortex were smoothed out to resemble that of the rat, for example, humans would need to have very large heads. Folding of the cortex provides about a one-third savings in space. The total surface area of the human cerebral cortex is about 2,200 to 2,400 cm<sup>2</sup>, but

because of the folding, about two thirds of this area is confined within the depths of the sulci. Another advantage of having a highly folded cortex is that neurons are brought into closer three-dimensional relationships to one another, saving axonal distance and hence neuronal conduction time between different areas. This savings occurs because the axons that make long-distance corticocortical connections run under the cortex through the white matter and do not follow the foldings of the cortical surface in their paths to distant cortical areas. In addition, by folding, the cortex brings some nearby regions closer together; for example, the opposing layers of cortex in each gyrus are in closer linear proximity than they would be if the gyri were flattened.

Although the cortex is composed of several cell layers in most regions, its thickness averages only 3 mm and ranges from 1.5 to 4.5 mm in different cortical regions. The cortex itself contains the cell bodies of neurons, their dendrites, and some of their axons. In addition, the cortex includes axons and axon terminals of neurons projecting to the cortex from other brain regions, such as the subcortical thalamus. The cortex also contains blood vessels. Because the cerebral cortex has such a high density of cell bodies, it appears grayish in relation to underlying regions that are composed primarily of axons of neurons and appear slightly paler or even white. As described earlier, for this reason anatomists used the terms *gray matter* and *white matter* when referring to areas of cell bodies and axon tracts, respectively. The latter tracts represent the billions of axons that connect the neurons of the cerebral cortex to other locations in the brain (Figure 3.9).

### ANATOMICAL SUBDIVISIONS

The cerebral hemispheres have four main divisions, or *lobes*—and a fifth, if you consider that the limbic system is sometimes referred to as the *limbic lobe*, as described later. These regions have different functional properties and can usually be distinguished from one another by prominent anatomical landmarks such as pronounced sulci. The names of the brain areas were derived from names originally given to the overlying skull bones; for example, the temporal lobe lies underneath the temporal bone. The temporal bone derived its name from the Latin *temporalis* (meaning “of time”) probably because of the graying of hair overlying the temporal bone—a sign of passing time if there ever was one.



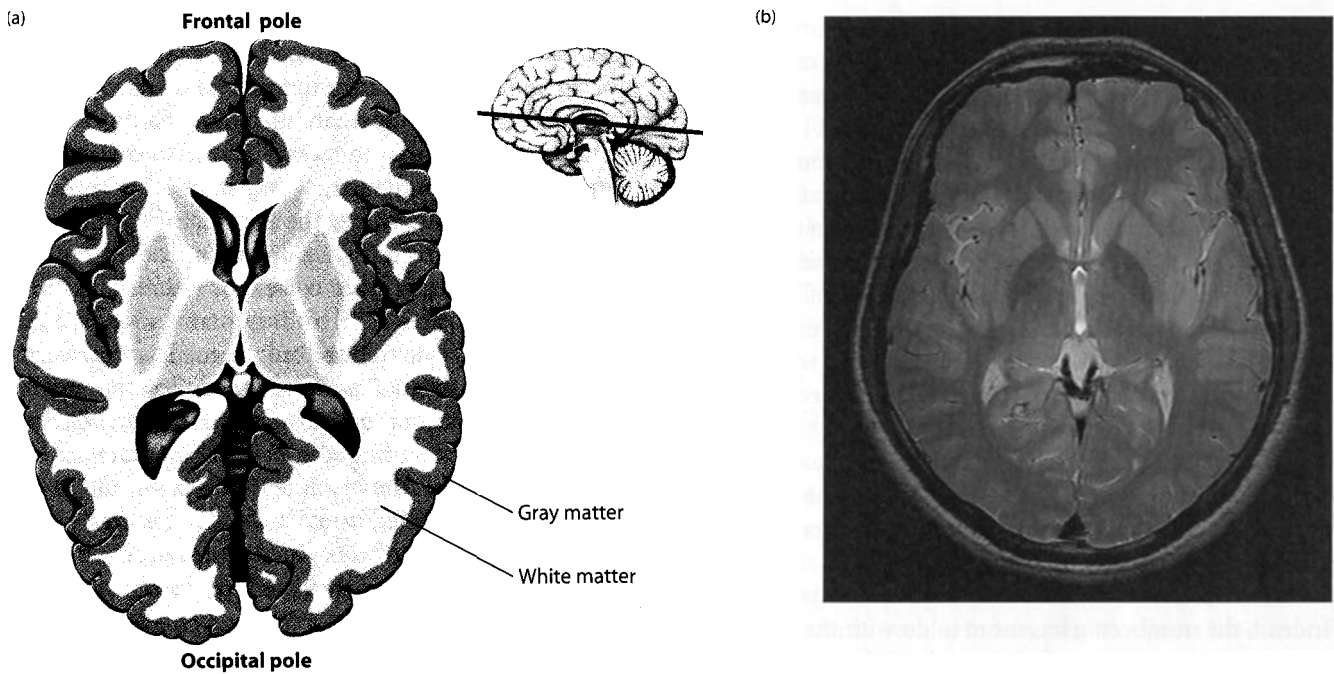
**Figure 3.8** Lateral view of the left hemisphere (a) and dorsal view of the cerebral cortex (b) in humans. The major features of the cortex include the four cortical lobes and various key gyri. Gyri are separated by sulci and result from the folding of the cerebral cortex that occurs during development of the nervous system, to achieve an economy of size.

The four lobes are the frontal, parietal, temporal, and occipital lobes (Figure 3.10). The central sulcus divides the **frontal lobe** from the **parietal lobe**, and the Sylvian (lateral) fissure separates the **temporal lobe** from the frontal and parietal lobes. The **occipital lobe** is demarcated from the parietal and temporal lobes by the parieto-occipital sulcus on the brain's dorsal surface and the preoccipital notch located on the ventrolateral surface. The left and right cerebral hemispheres are sepa-

rated by the interhemispheric fissure (also called the *longitudinal fissure*) that runs from the rostral to the caudal end of the forebrain.

Connections between the cerebral hemispheres are accomplished by axons from cortical neurons that travel through the **corpus callosum**, which represents the largest white matter **commissure** in the nervous system. *Commissure* is a special term for the white matter tracts that cross from the left to the right side, or vice versa, of





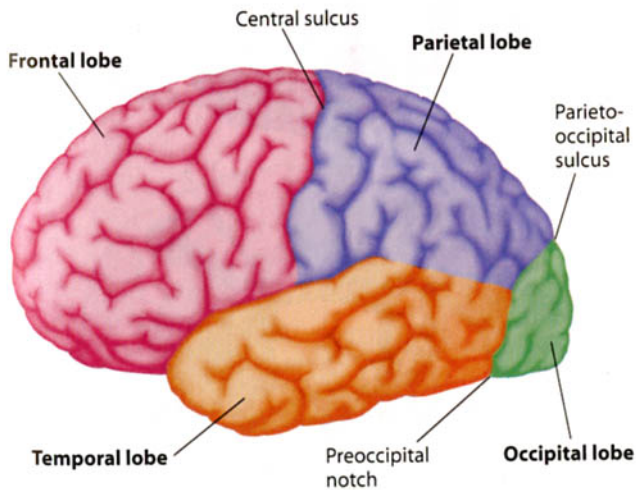
**Figure 3.9** (a) Horizontal section through the cerebral hemispheres at the level indicated at upper right. White matter is composed of myelinated axons, and gray matter is composed primarily of neurons. This diagram shows that the gray matter on the surface of the cerebral hemispheres forms a continuous sheet that is heavily folded. (b) High-resolution structural MRI in a similar plane of section in a living human. This T2 image was obtained on a 4-tesla scanner (a high-magnetic-field scanner) using a  $512 \times 512$  matrix for acquisition. Note that on T2 images the white matter appears darker than the gray matter. The skull and scalp can be seen here but are not shown in (a).

the CNS. The term *corpus callosum* means “hard body,” so named because of its tough consistency. Indeed, very early anatomists incorrectly believed that the corpus callosum served a structural function in supporting the cerebral hemispheres because it prevented them from

collapsing onto structures below. As we will discuss later in the book, the corpus callosum carries out valuable integrative functions for the two hemispheres.

### CYTOARCHITECTONICS

The cerebral cortex can be divided more finely than the four or five main lobes, in various ways. For example, it can be divided according to functional subdivisions of the cortex. But there are other, more purely anatomical criteria for subdividing the cortex. One is by the microanatomy of cell types and their organization. This method of subdividing is generally referred to as *cytoarchitectonics*—*cyto-* means “cell” and *architectonics* means “architecture”—and has to do with how cells in a region appear morphologically and are arranged with respect to each other. Cytoarchitectonic investigations entail the performance of detailed histological analysis of the tissue from different regions of the cerebral cortex. The goal is to define the extent of regions in which the cellular architecture looks similar and therefore might indicate a homogeneous area of the cortex that represents, perhaps, a functional area. This work began in earnest with Korbinian Brodmann at the beginning of the 20th century.

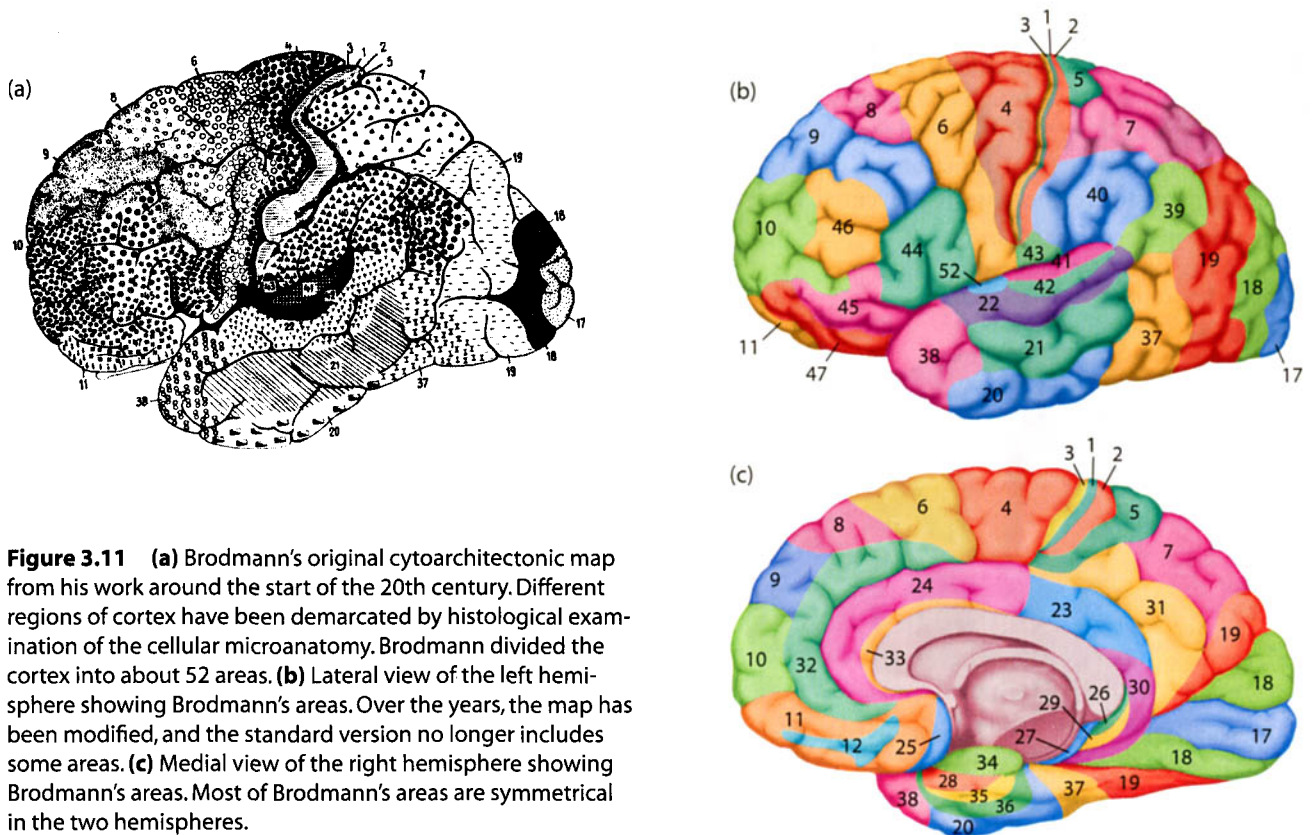


**Figure 3.10** Four lobes of the cerebral cortex, in lateral view of the left hemisphere. See text for details.

Brodmann (1909/1960) identified approximately 52 regions of the cerebral cortex. These areas were categorized according to differences in cellular morphology and organization, and numbered (Figure 3.11). Other anatomists further subdivided the cortex into almost 200 cytoarchitectonically defined areas, but many classified transition zones as separate areas when perhaps they should not be considered so. A combination of cytoarchitectonic and functional descriptions of the cortex is probably most effective in dividing the cerebral cortex into meaningful units; this type of work will likely continue into the foreseeable future because we are only beginning to learn the functional organization of the cerebral cortex. In the sections that follow, we use Brodmann's numbering system to describe the cerebral cortex, as well as anatomical names (e.g., superior temporal gyrus).

The Brodmann system often seems unsystematic. Indeed, the numbering has more to do with the order in which Brodmann sampled a region than with any meaningful relation between areas. Nonetheless, in some regions the numbering system has a rough correspondence with the relations between areas that carry out similar functions, such as vision—Brodmann areas

17, 18, and 19. It is worth noting here that the nomenclature of the cortex (and indeed the nervous system) is not uniform. Hence, a region might be referred to by its Brodmann name, a cytoarchitectonic name, a gross anatomical name, or a functional name; and functional names change rapidly as new information is gathered. For example, let's consider the naming of the first area in the cortex to receive visual inputs from the thalamus—the primary sensory cortex for vision. The Brodmann name is area 17 (or Brodmann area 17; i.e., BA17), another cytoarchitectonic name is *striate cortex* (owing to its striated appearance under the microscope), the gross anatomical name is *calcarine cortex* (the cortex surrounding the calcarine fissure in humans), and the functional name is *primary visual cortex*, which has been labeled area VI (for “visual area 1”) on the basis of studies of the visual systems of monkeys. The choice here of primary visual cortex as an example is fortuitous because all these different terms refer to the same cortical area. But for much of the cortex this is not the case; that is, different nomenclatures often do not refer to precisely the same area with a one-to-one mapping. BA18 of the visual system, for example, is not synonymous with V2 (for “visual area 2”).



**Figure 3.11** (a) Brodmann's original cytoarchitectonic map from his work around the start of the 20th century. Different regions of cortex have been demarcated by histological examination of the cellular microanatomy. Brodmann divided the cortex into about 52 areas. (b) Lateral view of the left hemisphere showing Brodmann's areas. Over the years, the map has been modified, and the standard version no longer includes some areas. (c) Medial view of the right hemisphere showing Brodmann's areas. Most of Brodmann's areas are symmetrical in the two hemispheres.



It is also possible to subdivide the cerebral cortex according to the general patterns of layering (Figure 3.12). Ninety percent of cortex is composed of **neocortex**, which typically contains six main cortical layers with a high degree of specialization of neuronal organization (see Figure 3.12c). Layer IV is typically the input layer, receiving information from the thalamus, as well as information from other, more distant cortical areas. Layer VI, on the other hand, is typically considered an output layer that sends information from the cortex back to the thalamus, facilitating feedback. Each layer is anatomically and functionally distinct, though it is important to note that information is shared between the layers via axonal projections.

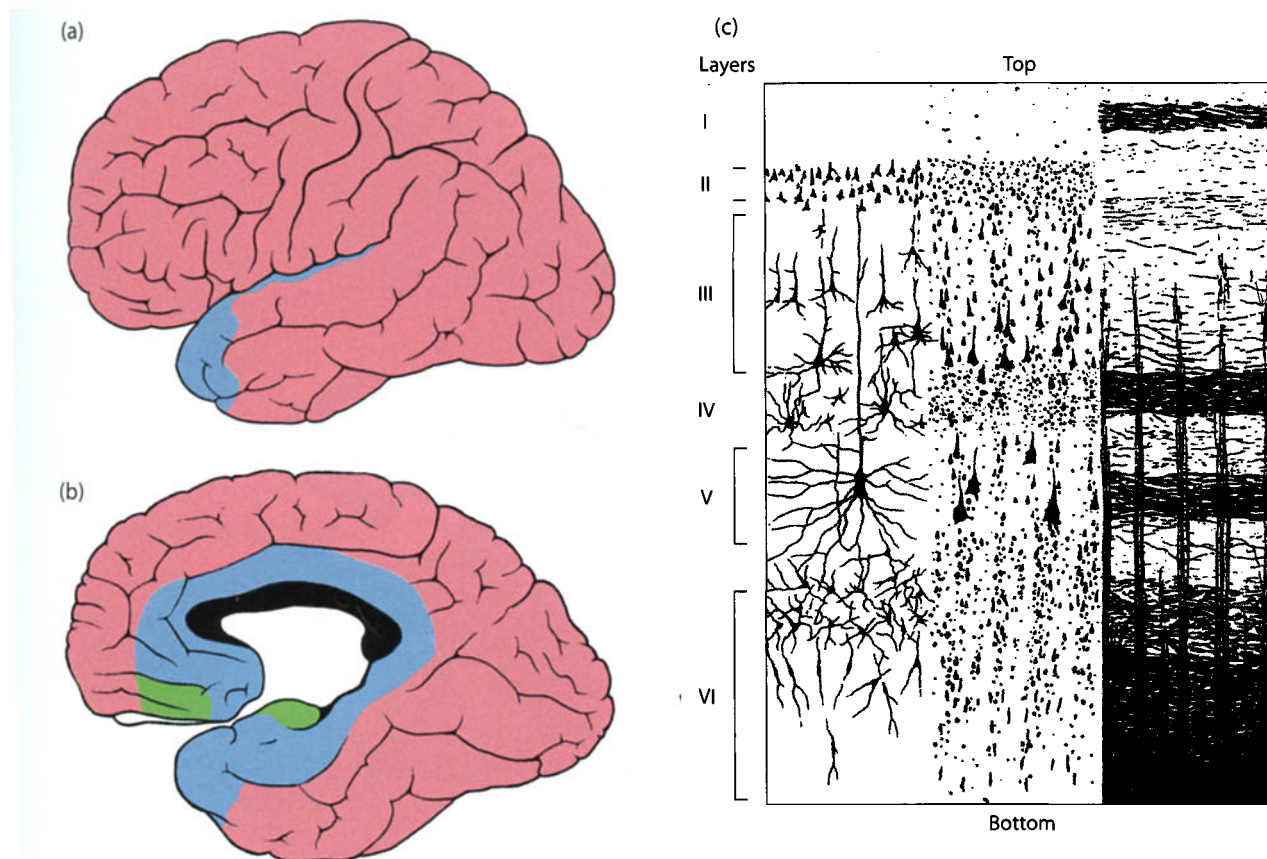
*Neocortex* includes areas like primary sensory and motor cortex and association cortex (areas not obviously primary sensory or motor). *Mesocortex* is a term for the so-called paralimbic region, which includes the cingulate gyrus, parahippocampal gyrus, insular cortex,

and the orbitofrontal cortex, all of which will be defined later. *Mesocortex* is interposed between neocortex and allocortex and has six layers. *Allocortex* typically has only one to four layers of neurons and includes the hippocampal complex (sometimes referred to as *archicortex*) and primary olfactory cortex (sometimes referred to as *paleocortex*). The take-home message here is that the cerebral cortex can be subdivided into major regions that differ according to the degree of complexity of the neuronal layering.

### FUNCTIONAL DIVISIONS

The lobes of the cerebral cortex have a variety of functional roles in neural processing. Major identifiable systems can be localized within each lobe, but systems of the brain also cross different lobes. That is, these brain systems do not map one to one onto the lobe in which they primarily reside, but in part the gross anatomical

**Figure 3.12** Cerebral cortex, color-coded to show the regional differences in cortical layering that specify different types of cortex. **(a)** The lateral surface of the left hemisphere. **(b)** The medial surface of the right hemisphere. Neocortex is shown in red, mesocortex in blue, and allocortex in green. **(c)** Idealized cross section of neocortex showing a variety of cell types and the patterns of three different types of staining techniques. On the left, the Golgi preparation is apparent: Only a few neurons are stained, but each is completely visualized. In the middle, we see primarily cell bodies from the Nissl stain. On the right, we see the fiber tracks in a Weigert stain, which selectively stains myelin.



## HOW THE BRAIN WORKS

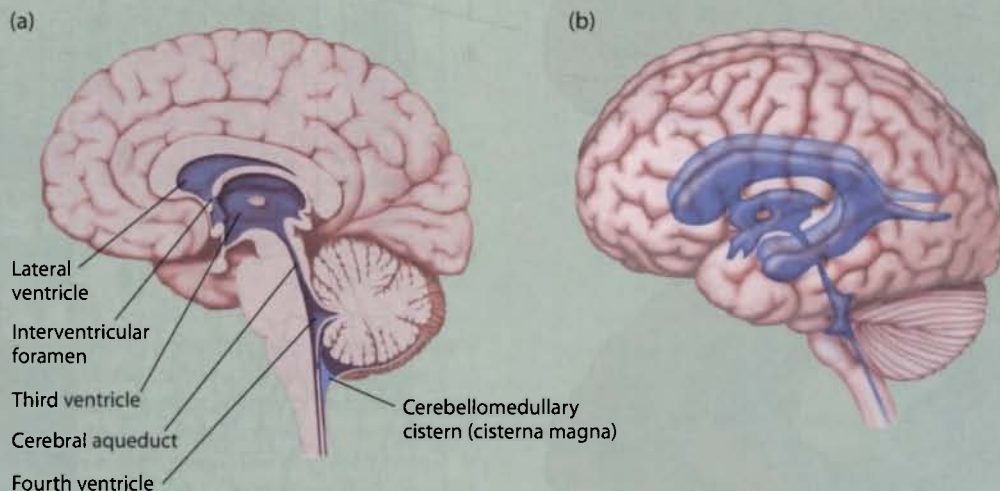
## The Chambers of the Mind

We have understood for many decades that neurons in the brain are functional units, and that how they are interconnected yields specific circuits for the support of particular behaviors. Centuries ago, early anatomists, believing that the head contained the seat of behavior, examined the brain to see where the conscious self (soul, if you wish) was located. They found a likely candidate: Some chambers in the brain seemed to be empty (except for some fluid) and thus were possible containers for higher functions. These chambers are called *ventricles* (see the figure). What is the function of these chambers within the brain?

The brain weighs a considerable amount but has little or no structural support; there is no skeletal system for the brain. To overcome this potential difficulty, the brain is immersed in a fluid called *cerebrospinal fluid* (CSF). This fluid allows the brain to float to help offset the pressure that would be present if the brain were merely sitting on the base of the skull. CSF also reduces shock to the brain and spinal cord during rapid acceler-

ations or decelerations, such as when we fall or are struck on the head.

The ventricles inside the brain are continuous with the CSF surrounding the brain. The largest of these chambers are the lateral ventricles, which are connected to the third ventricle in the brain's midline. The cerebral aqueduct joins the third to the fourth ventricle in the brainstem below the cerebellum. The CSF is produced in the lateral ventricles and in the third ventricle by the choroid plexus, an outpouching of blood vessels from the ventricular wall. Hence, CSF is similar to blood, being formed by the transport of what resembles an ultrafiltrate of blood plasma; essentially, CSF is a clear fluid containing proteins, glucose, and ions, especially potassium, sodium, and chloride. It slowly circulates from the lateral and third ventricles through the cerebral aqueduct to the fourth ventricle and on to the subarachnoid space surrounding the brain, to be reabsorbed by the arachnoid villi in the sagittal sinus (the large venous system located between the two hemispheres on the dorsal surface; not shown).



Ventricles of the human brain. (a) Midsagittal view. (b) Three-dimensional view.

subdivisions of the cerebral cortex can be related to different sensorimotor functions. In their principal organization, cognitive brain systems are often composed of networks whose component parts are located in different lobes of the cortex. Finally, most functions in the brain—whether sensory, motor, or cognitive—rely on both cortical and subcortical components. Because one of the goals of this book is to review what we know about the functional localization of higher cognitive and perceptual processes, what follows in this section is a beginner's guide to the functional anatomy of the cortex.

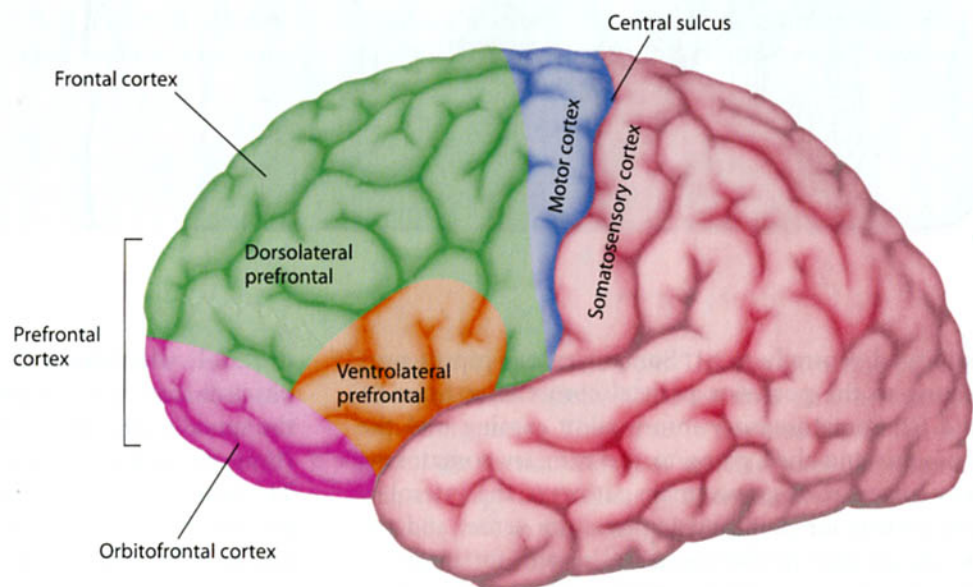
**Motor Areas of the Frontal Lobe** The frontal lobe plays a major role in the planning and execution of movements. It has two main subdivisions: the motor cortex and the prefrontal cortex. The motor cortex begins in the depths of the central sulcus and extends in the anterior direction. The primary motor cortex (M1) corresponds to BA4. It includes the anterior bank of the central sulcus and much of the precentral gyrus (the prefix *pre-* in neuroanatomy means “in front of”). Anterior to this area are two more main motor areas of cortex (within BA6): the premotor cortex on the lateral surface of the hemisphere, and the supplementary motor cortex that lies dorsal to the premotor area and extends around to the hemisphere's medial surface. These motor cortical areas contain motor neurons whose axons extend to the spinal cord and brainstem and synapse on motor neurons in the spinal cord. The output layer of motor cortex contains some of the most

amazing neurons in the nervous system: the large pyramidal neurons known as *Betz's cells*, named after Vladimir Aleksandrovich Betz, who described them. Betz's cells are the largest neurons in the cerebral cortex, reaching 60 to 80 mm in diameter at the cell body, with some sending axons several feet long down the spinal cord.

The more anterior regions of the frontal lobe, the **prefrontal cortex**, take part in the more complex aspects of planning and executing behavior—tasks that require the integration of information over time. The prefrontal cortex has three or more main areas that are commonly referred to in descriptions of the gross anatomy of the frontal lobe (although different definitions can be used): the dorsolateral prefrontal cortex, the orbitofrontal cortex (Figure 3.13), and the anterior cingulate and medial frontal regions (not visible in Figure 3.13, but refer to Figure 3.18).

**Somatosensory Areas of the Parietal Lobe** The somatosensory cortex is in the posterior bank of the central sulcus and encompasses the postcentral gyrus and adjacent areas (Brodmann areas 1, 2, and 3). These cortical regions receive inputs from the somatosensory relays of the thalamus and represent information about touch, pain, temperature sense, and limb proprioception (limb position). The primary somatosensory cortex (or S1) is immediately caudal to the central sulcus, and a secondary somatosensory cortex (S2), receiving information via projections primarily from S1,

**Figure 3.13** Divisions of the frontal cortex. The frontal lobe contains both motor and higher order association areas. For example, the prefrontal cortex is involved in executive functions, memory, and other processes.





## HOW THE BRAIN WORKS

## Cortical Topography

Early insights into human cortical organization were made possible by studies that involved direct stimulation of the cortex of awake humans undergoing brain surgery. Wilder Penfield and Herbert Jasper (1954) at the Montreal Neurological Institute carried out such pioneering work in the 1940s. Taking advantage of the fact that the cortex is exposed during surgery, these surgeons removed damaged brain tissue and systematically explored the effects of small levels of electrical current applied to the cortical surface. Panel (a) of the figure shows the exposed cortex of an epileptic patient and panel (b), a gridwork of electrodes laid over the surface for stimulation and recording; stimulation during surgery can be done with a single electrode rather than a grid. Because there are no pain receptors in the central nervous system, patients experience no discomfort from stimulation. Thus, stimulation can be applied even when they are awake and fully conscious, enabling researchers to gather the patients' subjective experiences—a relative impossibility in animal studies.

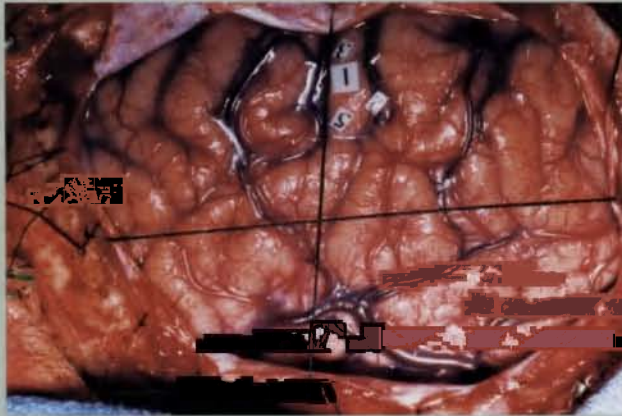
In their studies, Penfield and his associates found a topographic correspondence between cortical regions and body surface with respect to somatosensory and motor processes. This correspondence is represented in panel (c) by overlaying drawings of body parts on drawings of coronal sections of the motor and somatosensory cortex. These coronal sections are from the regions indicated by the color codes in the lateral view of the whole brain at the top of panel (c) (only the

left hemisphere is shown here, representing the right body surface). The resulting map of the body surface on the cortex is sometimes called a *homunculus*, referring to the fact that there is an organized representation of the body across a given cortical area. Note that there is an indirect relation between the actual size of body parts and the cortical representation of the body's parts. For example, areas within the motor homunculus that activate muscles in the fingers, mouth, and tongue are much larger than would be expected if the representation were proportional. The large drawings of the fingers and mouth indicate that large areas of cortex are involved in the fine coordination required when we manipulate objects or speak.

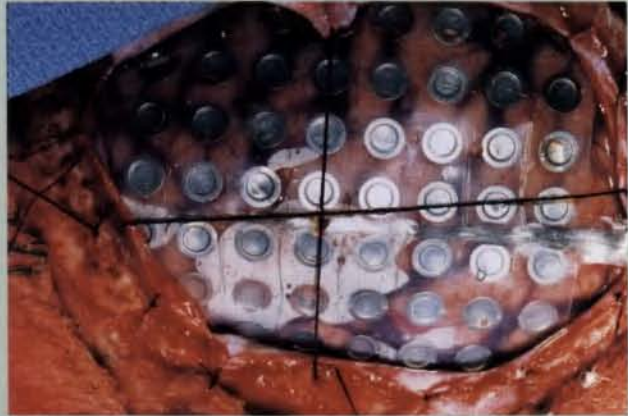Is the representation of the homunculus in the figure correct? Recent evidence from brain-imaging studies using a technique described in Chapter 4—functional magnetic resonance imaging (fMRI)—suggests that it may not be. Ravi Menon and his colleagues (Servos et al., 1999) in Canada stimulated the foreheads and chins of healthy volunteers while their brains were being scanned. In contrast to the results of the electrical-stimulation studies, they found that stimulating the forehead produced activity in a region that was below (inferior to) the region for activity related to chin stimulation—the reverse of the drawing in the figure based on the work of Penfield and his colleagues. If the latter pattern from neuroimaging turns out to be accurate, it will constitute a dramatic example of scientific revisionism.

is located ventrally to S1. Somatosensory inputs projecting to the posterior parietal cortex arise from S1 and S2. Somatosensory information coming into the thalamus and then going to the primary somatosensory cortex traverses two main pathways: the anterolateral system for pain and temperature sense, and the dorsal column–medial lemniscal system for information about touch, proprioception, and movement (Fig-

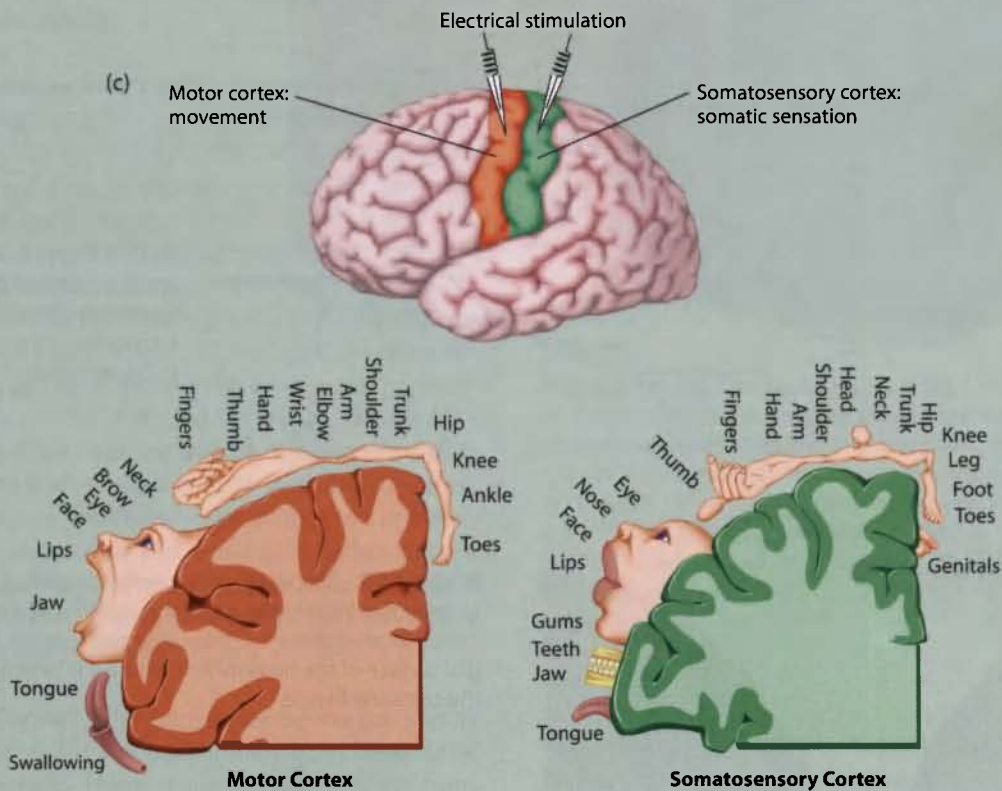
ure 3.14). Receptor cells in the periphery transduce physical stimuli into neuronal impulses conducted to the spinal cord and toward the brain, making synaptic connections at relay sites along the ascending pathway. The two systems for somatosensory information take slightly different paths in the spinal cord, brainstem, and midbrain on their route to the thalamus, and then to the cortex.



(a)



(b)

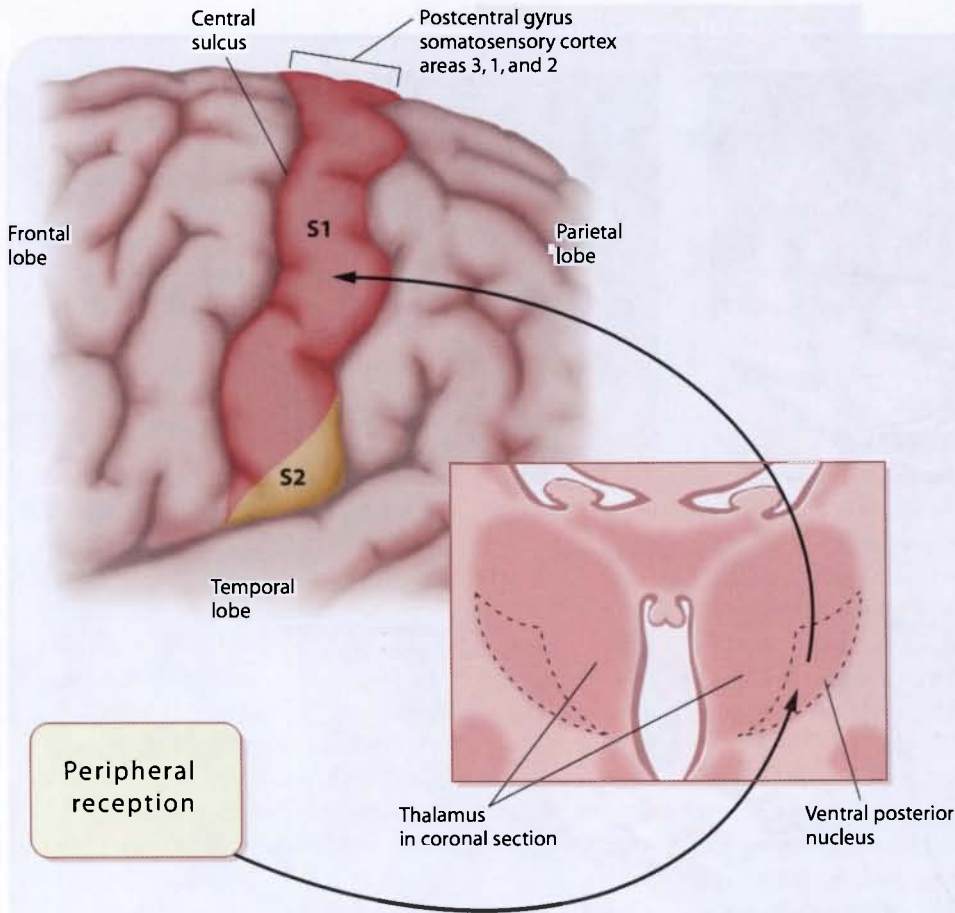


**Visual Processing Areas in the Occipital Lobe** The primary visual cortex (also known as *striate cortex* because its surface anatomical organization makes it appear striped to the naked eye, *V1* for visual area 1, or *BA17*) receives visual inputs relayed from the lateral geniculate nucleus of the thalamus (Figure 3.15). In humans, the primary visual cortex is on the medial surface of the cerebral hemispheres, extending only slightly onto the

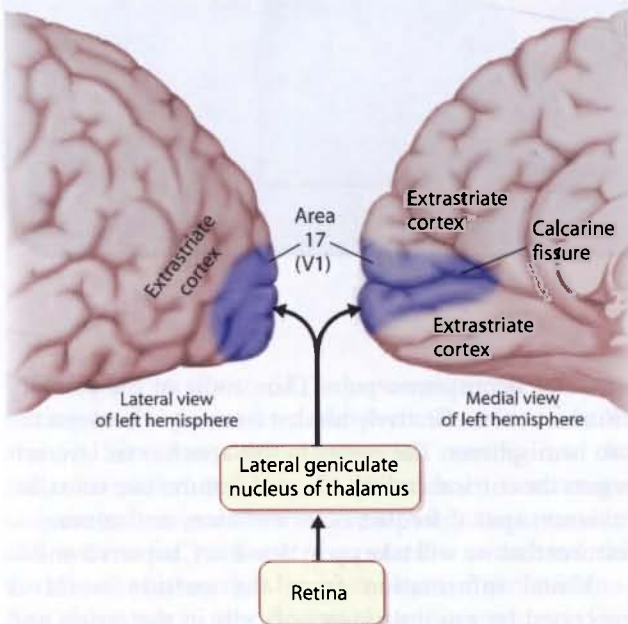
posterior hemispheric pole. Thus, most of the primary visual cortex is effectively hidden from view, between the two hemispheres. The cortex in this area has six layers; it begins the cortical coding of visual features like color, luminance, spatial frequency, orientation, and motion—features that we will take up in detail in Chapters 5 and 6.

Visual information from the outside world is processed by multiple layers of cells in the retina and





**Figure 3.14** The somatosensory cortex, which is located in the postcentral gyrus. Inputs from peripheral receptors project via the thalamus (shown in cross section) to the primary somatosensory cortex (S1). Secondary somatosensory cortex (S2) is also shown.



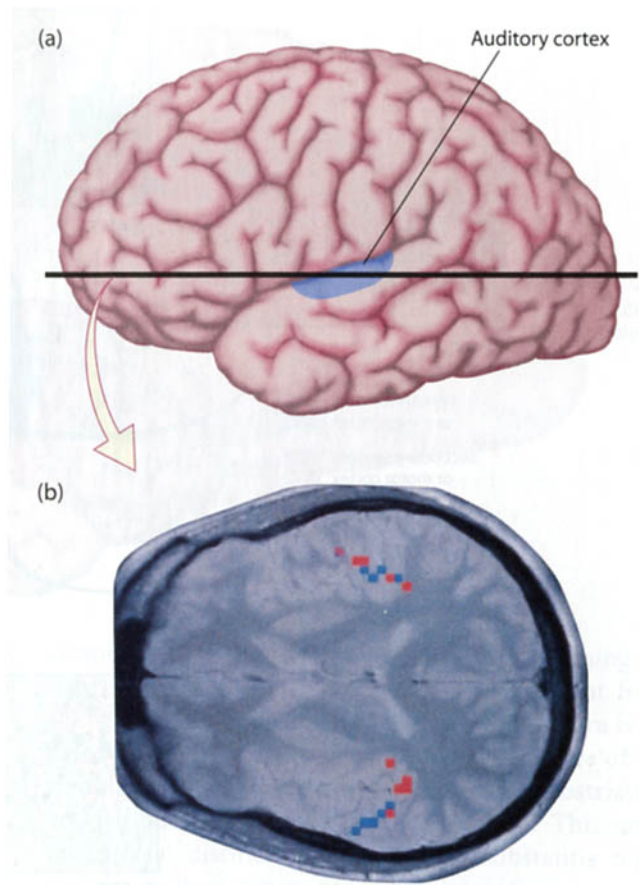
**Figure 3.15** The visual cortex, which is located in the occipital lobe. Brodmann area 17, also called the *primary visual cortex* (V1), is located at the occipital pole and extends onto the medial surface of the hemisphere, where it is largely buried within the calcarine fissure.

transmitted via the optic nerve to the lateral geniculate nucleus of the thalamus, and from there to V1—a pathway often referred to as the *retinogeniculostriate*, or *primary visual pathway*. Note that visual projections from the retina also reach other subcortical brain regions by way of secondary projection systems. The superior colliculus of the midbrain is the main target of the secondary pathway and participates in visuomotor functions such as eye movements. In Chapter 12 we will review the role of the cortical and subcortical projection pathways in visual attention.

Surrounding the striate cortex is a large visual cortical region called the *extrastriate* (“outside the striate”) visual cortex (sometimes referred to as the *prestriate* cortex in monkeys, to signify that it is anatomically anterior to the striate cortex). The extrastriate cortex includes BA18 and BA19.

**Auditory Processing Areas in the Temporal Lobe** The auditory cortex lies in the superior part of the temporal lobe and is buried within the Sylvian fissure (Figure 3.16). The projection from the cochlea (the auditory sensory organ in the inner ear) proceeds through the subcortical relays to the medial geniculate of the thalamus, and then to the supratemporal cortex in a region known as *Heschl’s gyri*. This region represents A1, the primary auditory cortex, and A2, the auditory association area surrounding it and posterior to the primary auditory cortex (BA41 and BA42). BA22, which surrounds the auditory cortex, aids in the perception of auditory inputs; when this area is stimulated, sensations of sound are produced in humans. One can represent the sensory inputs to the auditory cortex using a tonotopic map; the orderly representation of sound frequency within the auditory cortex can be determined with several tonotopic maps.

**Association Cortex** The portion of neocortex that is not sensory or motor has traditionally been termed the **association cortex**. These regions receive inputs from many cortical areas, contain cells that may be activated by more than one sensory modality, and have specific functional roles that are not exclusively sensory or motor. For example, take the visual association cortex. Though the primary visual cortex is necessary for normal vision, neither it nor the extrastriate cortex is the sole locus of visual perception. Regions of visual association cortex in the parietal and temporal lobes are important for correct perception of the visual world (see Chapters 5 and 6). Moreover, visual association cortex can be activated during mental imagery when we call up a visual memory even in the absence of visual stimula-

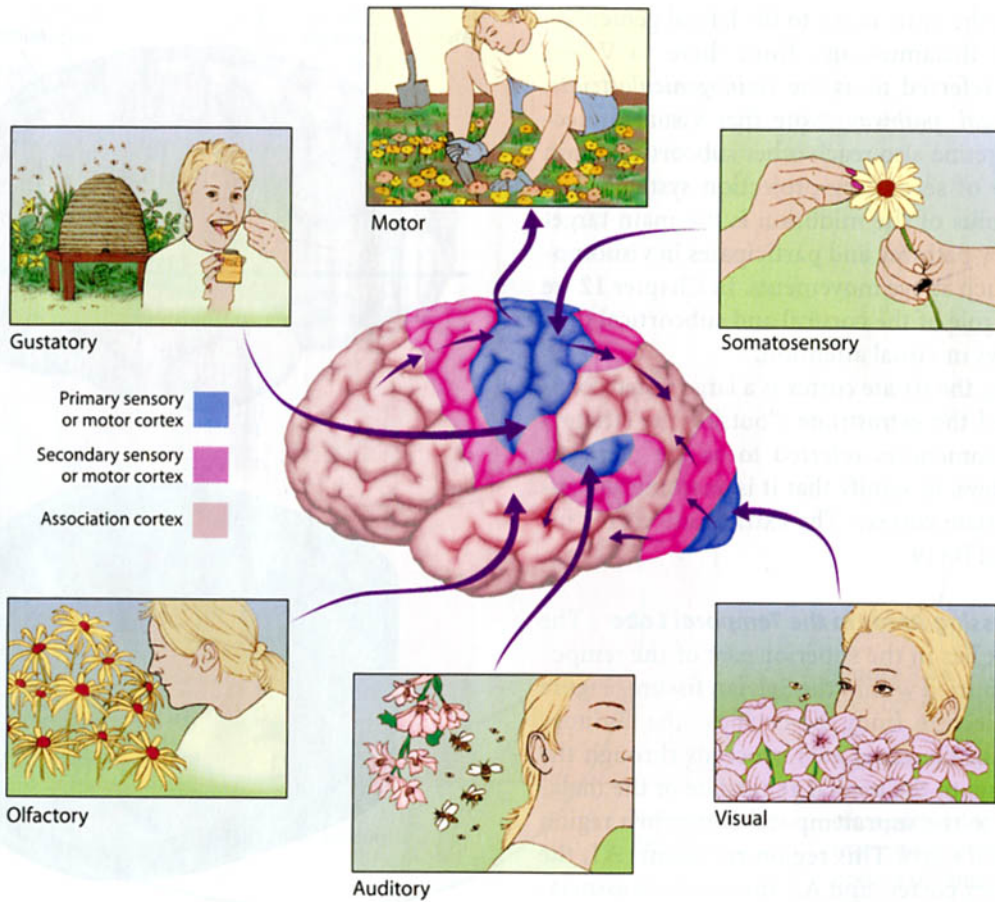


**Figure 3.16** (a) Primary auditory cortex, which is located in the superior temporal lobe. The primary auditory cortex and surrounding association auditory areas contain representations of auditory stimuli and show a tonotopic organization. (b) This MRI shows areas of the superior temporal region in horizontal section that have been stimulated by tones of different frequencies and show increased blood flow as a result of neuronal activity.

tion. As another example, the association areas of the parietal–temporal–occipital junction of the left hemisphere have a prominent role in language processing, whereas this region in the right hemisphere is implicated in attentional orienting (see Chapter 12). Thus, higher mental processes are the domain of the association cortical areas, in interaction with sensory and motor areas of cortex (Figure 3.17).

### Limbic System, Basal Ganglia, Hippocampus, and Diencephalon

In the preceding sections we focused on the neocortex. Here we will consider the mesocortical and allocortical



**Figure 3.17** Primary sensory and motor cortex and surrounding association cortex. The blue regions show the primary cortical receiving areas of the ascending sensory pathways and the primary output region to the spinal cord. The secondary sensory and motor areas are colored red. The remainder is considered association cortex.

regions of the cerebrum. Then we will look at the subcortical structures of the basal ganglia and the diencephalon.

### LIMBIC LOBE

Let's look at the portions of the forebrain that are collectively known as the limbic lobe or **limbic system** (Figure 3.18). These include several structures that form a border (in Latin, *limbus*) around the brainstem, named the *grand lobe limbique* by Paul Broca (see Chapter 1). A band of cortex known as the cingulate gyrus extends above the corpus callosum in the anterior–posterior direction. Together, the cingulate gyrus, hypothalamus, anterior thalamic nuclei, and hippocampus constitute the “classical” limbic lobe (Figure 3.19). In the 1930s James Papez (pronounced “payps”) first suggested the idea that these structures were organized into a system for emotional behavior, which led to use of the term *Papez circuit*.

Since that initial formulation, much has been learned about the structures participating in the limbic

system, and today the **amygdala**, a group of neurons anterior to the hippocampus, is usually considered a key component, along with the orbitofrontal cortex and parts of the basal ganglia (described in the next section, but not shown in Figure 3.19); in some descriptions, the medial dorsal nucleus of the thalamus is also included. The organization and role of the limbic system are described in more detail in Chapter 9. The limbic system participates in emotional processing, learning, and memory. With each passing year we discover new functions of this system.

### BASAL GANGLIA

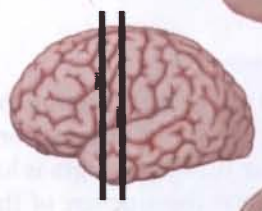
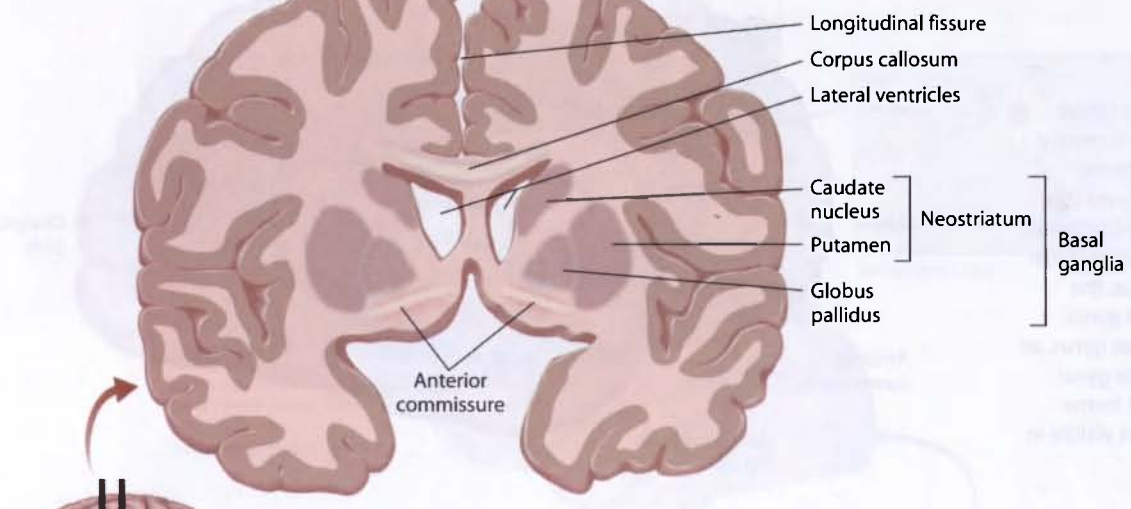
The **basal ganglia** are a collection of subcortical neuronal groups in the forebrain located beneath the anterior portion of the lateral ventricles (see “How the Brain Works: The Chambers of the Mind,” on p. 72). The basal ganglia have a significant role in the control of movement. The three main subdivisions are the globus pallidus, caudate nucleus, and putamen (Figure



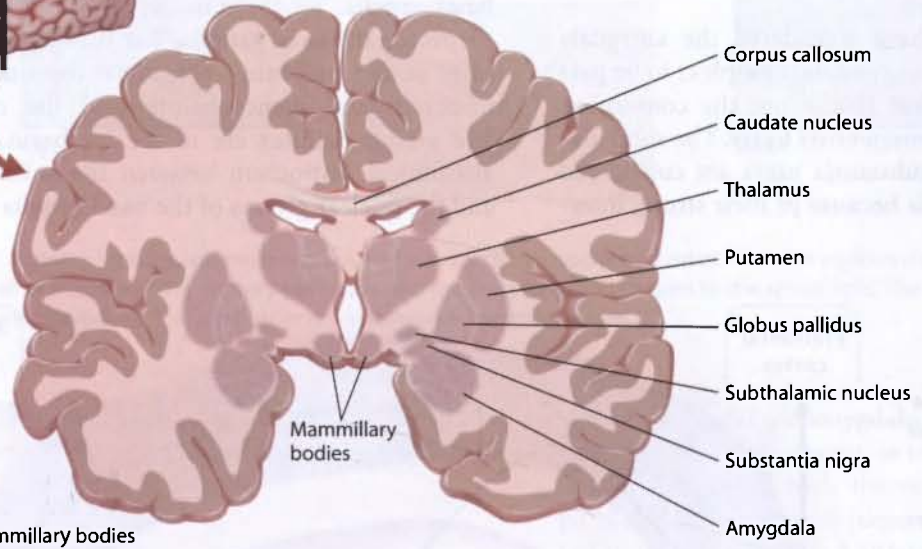


(a)

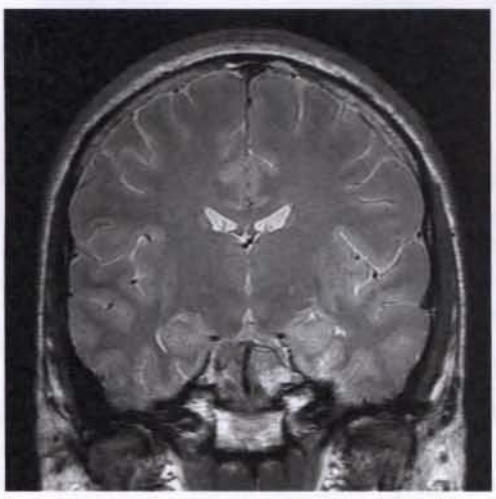
Level of anterior commissure



Level of mammillary bodies



(b)



**Figure 3.20** (a) Cross sections through the brain at two anterior–posterior levels (as indicated), showing the basal ganglia. (b) Corresponding high-resolution, structural MRI (4-tesla scanner) taken at approximately the same level as the more posterior drawing in (a). This image also shows the brainstem, as well as the skull and scalp, which are not shown in (a).

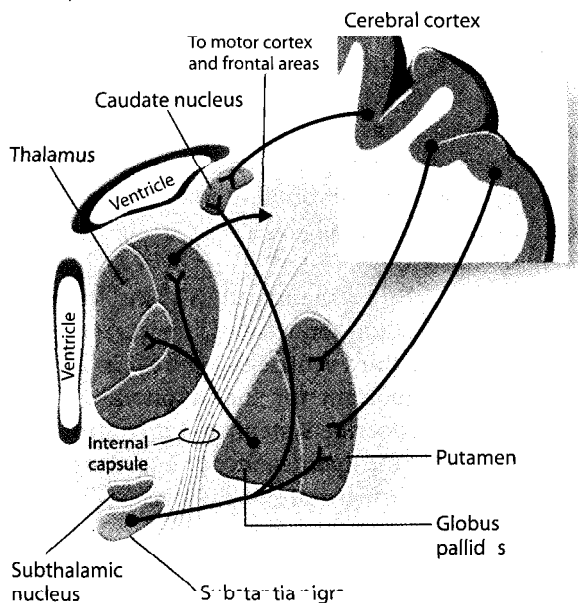


as important as the microanatomical (cellular) and functional relationships, however. We will return to this idea with respect to the basal ganglia in detail in Chapter 7.

The basal ganglia, subthalamic nucleus, and substantia nigra participate in circuits with the cortex and thalamus to mediate aspects of motor control (both somatic motor and oculomotor systems), as well as some cognitive functions.

The primary circuits projecting to the basal ganglia include a corticostriatal projection that contains direct projections from all major cortical regions onto neurons in the caudate and putamen, which are the input structures of the basal ganglia. In addition, motor areas of cortex can project to the basal ganglia via the cell groups in the thalamus and the subthalamic nucleus. The major outputs of the basal ganglia project from the globus pallidus to thalamic nuclei and then to cortex—primarily motor and premotor cortex, as well as prefrontal cortex (Figure 3.21). Thus, the basal ganglia are not in a projection pathway from motor cortical areas to the spinal cord, to control muscular activity directly, but instead are part of a cortical–subcortical motor loop that is thought to monitor aspects of how motor activity, as well as nonmotoric functions are progressing.

**Figure 3.21** Major inputs and outputs of the basal ganglia. The basal ganglia form a cortical–subcortical motor loop that monitors motor behavior.



## HIPPOCAMPAL FORMATION AND MEDIAL TEMPORAL LOBE

The region of the forebrain along the ventral medial surface of the temporal lobe contains the **hippocampus** and the associated areas of the dentate gyrus, parahippocampal gyrus, and entorhinal cortex—the latter being the anterior portion of the parahippocampal gyrus (BA28) (Figure 3.22). The hippocampus and dentate gyrus are composed of three- or four-layer cortex (archicortex), whereas entorhinal cortex and the parahippocampal gyrus in humans are composed of six-layer cortex (although it is mesocortex, not neocortex).

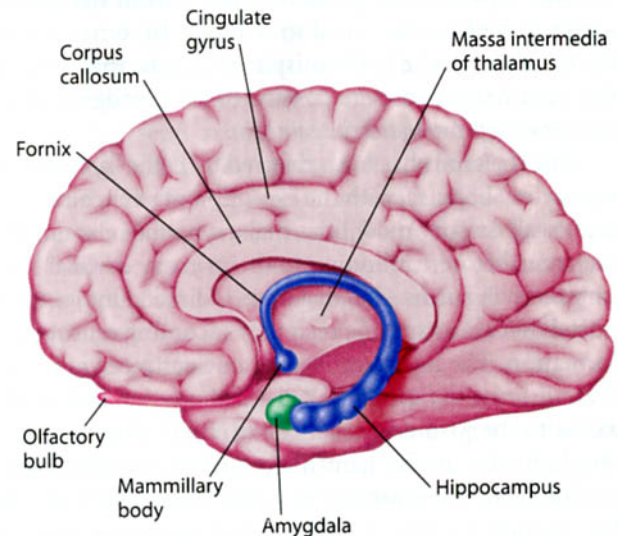
The hippocampus has been subdivided into zones referred to as the *CA fields* (*cornu ammonis* is Latin for “horn of Ammon”), which are divided into CA1, CA2, CA3, and CA4 based on differences in cellular morphology, connectivity, and development (Figure 3.23). As we will see in Chapter 8, the hippocampus plays a central role in memory or, to be more precise, learning.

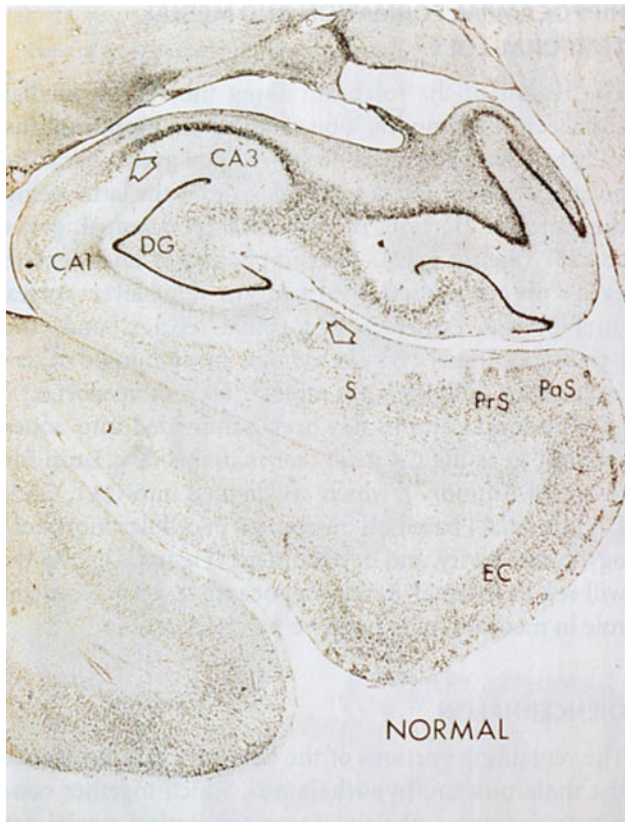## DIENCEPHALON

The remaining portions of the forebrain to consider are the **thalamus** and **hypothalamus**, which together constitute the diencephalon. These subcortical nuclei are composed of groups of specialized cells with interconnections to widespread brain areas.

**Thalamus** Although its name is Greek for “inner chamber,” the thalamus is not actually hollow. It lies at

**Figure 3.22** Anatomy of the hippocampal formation. The hippocampus is located on the inferior and medial aspect of the temporal lobe.

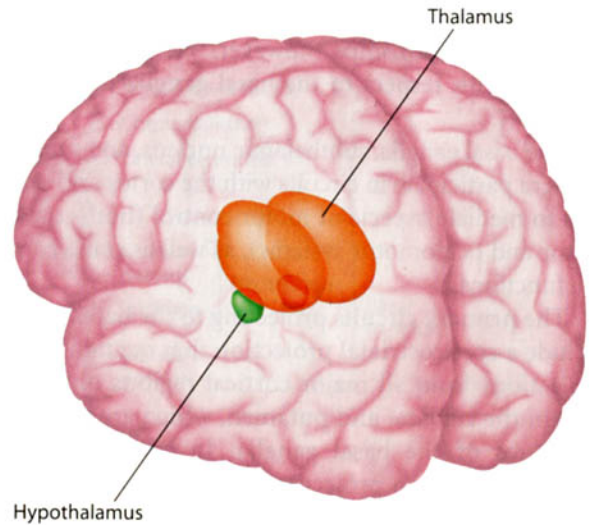




**Figure 3.23** Histological slide of a cross section through the hippocampus. The dentate gyrus (DG), entorhinal cortex (EC), and subiculum (S) can be seen, as well as cells of CA fields. The presubiculum (PrS) and parasubiculum (PaS) are also labeled.

the most rostral end of the brainstem (Figure 3.24), in the dorsal part of the diencephalon in each hemisphere, and is bordered medially by the third ventricle, dorsally by the fornix and corpus callosum, and laterally by the internal capsule—the projection fibers from the motor cortex to the brainstem and spinal cord. In some people, the thalamus in the left hemisphere and the thalamus in the right hemisphere are connected by a bridge of gray matter called the *massa intermedia*.

The thalamus has been referred to as the “gateway to the cortex” because, with the exception of some olfactory inputs, all sensory modalities make synaptic relays in the thalamus before continuing to the primary cortical sensory receiving areas. The thalamus is divided into several nuclei that act as specific relays for incoming sensory information. The lateral geniculate nucleus receives information from the ganglion cells of the retina and sends axons to the primary visual cortex, BA17 (Figure 3.25). Similarly, the medial geniculate nucleus receives information from the inner ear, via other brainstem nuclei in the ascending auditory pathway, and sends axons to the



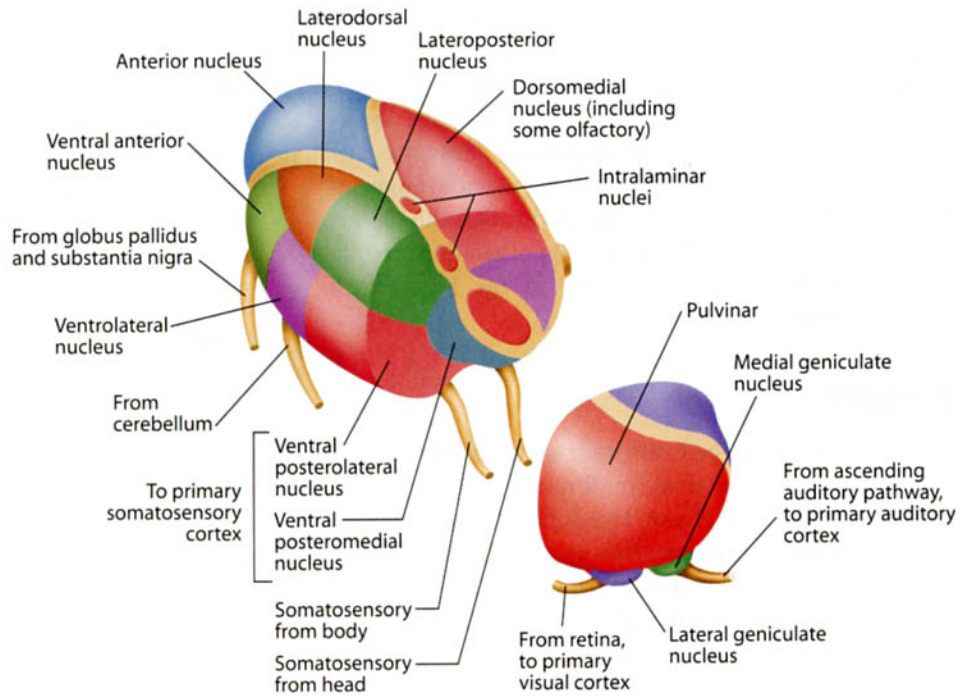
**Figure 3.24** Gross anatomy of the thalamus. This diagram shows the thalamus of the left and right hemispheres in a see-through brain. The thalamus is egg shaped. It serves as the gateway to the cortex for the sensory systems and contains reciprocal loops with all cortical regions, organized according to subdivisions of the thalamus. The thalamus also is innervated by brainstem projection systems.

primary auditory cortex (A1). Somatosensory information projects via the ventral posterior (medial and lateral) nuclei of the thalamus and then to primary somatosensory cortex in BA1, BA2, and BA3. Sensory relay nuclei of the thalamus not only project axons to the cortex but also receive heavy descending projections back from the same cortical area that they contact.

Not only is the thalamus involved in relaying primary sensory information, but also it receives inputs from the basal ganglia, cerebellum, neocortex, and medial temporal lobe and sends projections back to these structures to create circuits involved in many different functions. One important structure within the thalamus is the pulvinar nucleus, located at the posterior pole of the thalamus, which is involved in integrative functions involving multiple cortical areas.

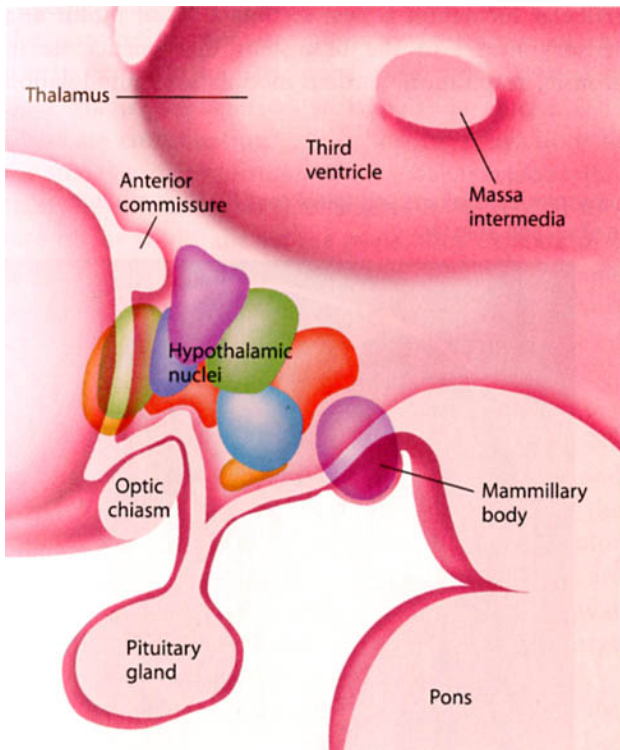
**Hypothalamus** Below the thalamus is the hypothalamus, a small collection of nuclei and fiber tracts that lie on the floor of the third ventricle (Figure 3.26). The hypothalamus is important for the autonomic nervous system and the endocrine system, and it controls functions necessary for the maintenance of homeostasis (i.e., maintaining the normal state of the body). The hypothalamus is also involved in emotional processes and in control of the pituitary gland, which is attached to the base of the hypothalamus.





**Figure 3.25** The left thalamus, showing inputs and outputs and major subdivisions. The various subdivisions of the thalamus serve different sensory systems and participate in various cortical–subcortical circuits. The posterior portion of the thalamus (**lower right**) is cut away in cross section and separated from the rest of the thalamus to reveal the internal organization of the thalamic nuclei (**upper left**).

**Figure 3.26** Midsagittal view of the hypothalamus. Various nuclear groups are shown diagrammatically. The hypothalamus is the floor of the third ventricle, and, as the name suggests, it sits below the thalamus. Anterior is to the left in this drawing.



The hormones produced by the hypothalamus control much of the endocrine system. For example, hypothalamic neurons in the region that surrounds the third ventricle send axonal projections to an area at the border of the hypothalamus and pituitary gland—the median eminence—where releasing factors (e.g., peptides) are released into the system that provides circulation to the anterior pituitary gland. In the anterior pituitary, these hypothalamic peptides trigger (or inhibit) the release of a variety of hormones into the bloodstream; growth hormone, thyroid-stimulating hormone, adrenocorticotropic hormone, and the gonadotropic hormones are examples of those released by the cells of the anterior pituitary under hypothalamic control. Hypothalamic neurons in the anteromedial region, including the supraoptic nucleus and paraventricular nuclei, send axonal projections into the posterior pituitary, where they stimulate the posterior pituitary to release the hormones vasopressin and oxytocin into the blood to regulate water retention in the kidneys, and milk production and uterine contractility, respectively. The hypothalamus receives inputs not only from the limbic cortex but also from other brain areas, including the mesencephalic reticular formation, amygdala, and the retina, to control circadian rhythms (light–dark cycles). Projections from the hypothalamus include a major projection to the prefrontal cortex, amygdala, and spinal cord. One of the most prominent projections is the one to the pituitary.



In addition to the direct neuronal projections of the hypothalamus, one important manner in which the hypothalamus influences the activity of other neurons is via neuromodulatory processes that involve the secretion of peptide hormones into the blood. These circulating peptide hormones can influence a wide range of behaviors by acting on distant sites through the bloodstream. In a similar fashion, the hypothalamus can be affected by hormones circulating in the blood, and thereby produce a neural response.

## Brainstem

We usually think of the **brainstem** as having three main parts: the mesencephalon (midbrain), metencephalon (pons), and myelencephalon (medulla). These three sections form the central nervous system between diencephalon and spinal cord. Compared to the vast bulk of the forebrain, the brainstem is rather small (Figure 3.27). It contains groups of motor and sensory nuclei, nuclei of widespread modulatory neurotransmitter systems, and white matter tracts of ascending sensory information and descending motor signals.

The organization becomes more complex as it proceeds from the spinal cord through the medulla, pons, and midbrain to the diencephalon and cerebral cortex. This neuronal complexity reflects the increasingly complex behaviors that these regions enable. However, this does not mean that the brainstem is unimportant or simplistic in its processing, nor does it signify that the brainstem's functions are ancillary. Indeed, damage to the brainstem is highly life threatening, in part because

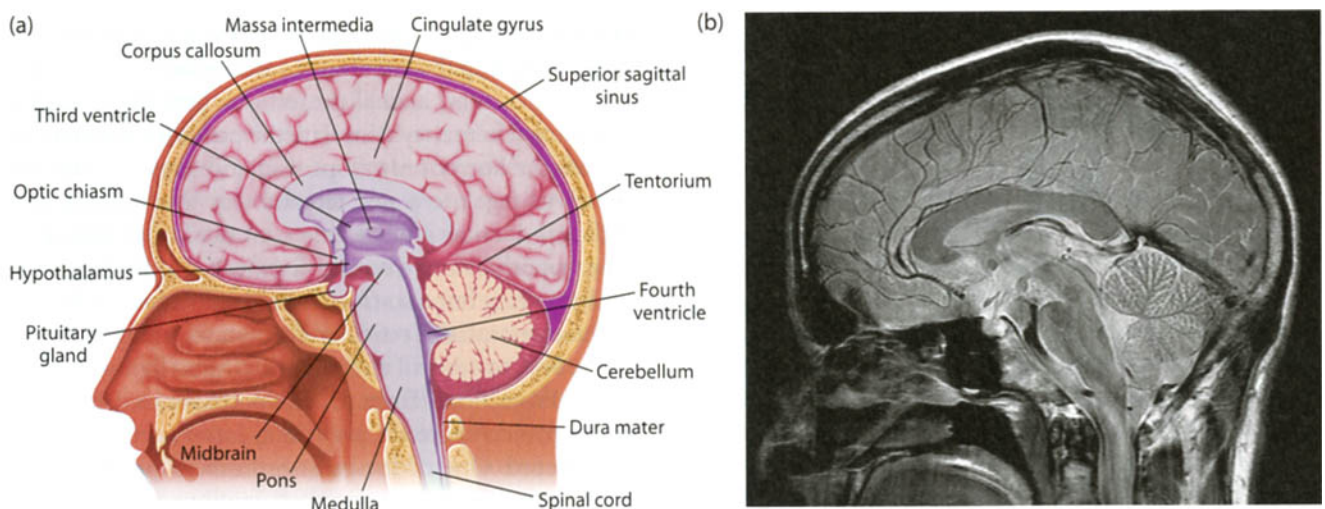
of the brainstem's size—being small means that a small lesion encompasses a large percentage of the tissue—and also because brainstem nuclei control respiration and even states of consciousness such as sleep and wakefulness. Therefore, damage to the brainstem can often be fatal, whereas damage to the cerebral cortex may have (relatively) minor consequences, depending on where and how extensive the cortical damage is.

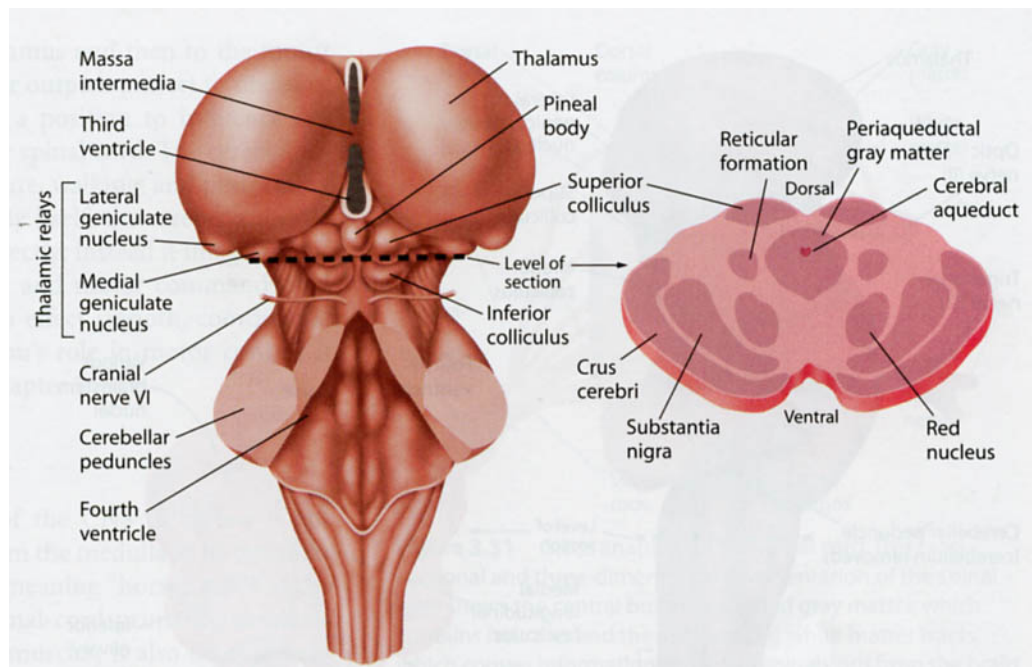
## MIDBRAIN

The mesencephalon, or **midbrain**, lies caudal to the diencephalon and is bounded posteriorly by the pons. It surrounds the cerebral aqueduct, which connects the third and fourth ventricles and consists of the *tectum* (meaning “roof,” representing the dorsal portion of the mesencephalon), *tegmentum* (the main portion of the midbrain), and ventral regions occupied by large fiber tracts (*crus cerebri*) from the forebrain to the spinal cord (corticospinal tract), cerebellum, and brainstem (corticobulbar tract). The midbrain contains neurons that participate in visuomotor functions (e.g., superior colliculus, oculomotor nucleus, trochlear nucleus), visual reflexes (e.g., pretectal region), and auditory relays (*inferior colliculus*); and the mesencephalic tegmental nuclei involved in motor coordination (red nucleus) (Figure 3.28).

Much of the midbrain is occupied by the mesencephalic reticular formation, a rostral continuation of the pontine and medullary reticular formation. The reticular formation is best seen as a set of motor and sensory nuclei in the brainstem that participate in arousal, respiration, cardiac modulations, modulation

**Figure 3.27** (a) Midsagittal section through the head, showing the brainstem, cerebellum, and spinal cord. (b) High-resolution structural MRI obtained with a 4-tesla scanner, showing the same plane of section as in (a).





**Figure 3.28** Anatomy of the midbrain. The dorsal surface of the brainstem is shown with the cerebral cortex and cerebellum removed. Cross section is through the midbrain at the level of the superior colliculus, the subcortical visuomotor nuclei.

of reflex muscular activity at the segmental level (i.e., in the limbs), and pain regulation.

### PONS AND MEDULLA

The last areas of the brainstem to consider are the metencephalon (pons) and myelencephalon (medulla). Together they form the hindbrain. The **pons** includes the pontine tegmental regions on the floor of the fourth ventricle, and the pons itself, a vast system of fiber tracts interspersed with pontine nuclei. The fibers are continuations of the cortical projections to the spinal cord, brainstem, and cerebellar regions; initially they are compact fiber tracts on the ventral surface of the midbrain. At the pons, they explode into smaller tracts that continue to their final destinations as they course around the pontine nuclei, some terminating on neurons in this region (the pons is labeled in Figure 3.27a).

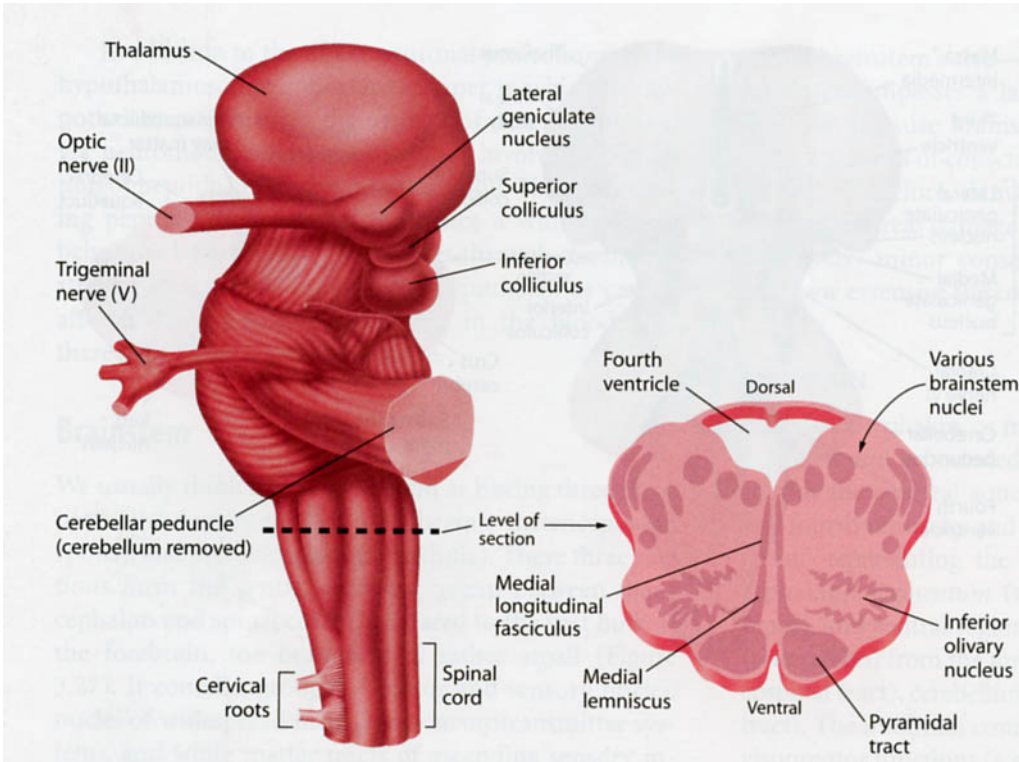
The many nuclei at the pontine level have auditory and vestibular (balance) functions; primary CNS synapses of axons coming from the auditory and vestibular periphery are located in cell groups of the pontine tegmentum. In addition, sensory and motor nuclei from the face and mouth are located here, as are visuomotor nuclei controlling some of the extraocular muscles. This level of the brainstem also contains a large portion of the reticular formation.

Finally, the brain's most caudal portion is the **medulla**, which is continuous with the spinal cord. The

medulla has two prominent bilateral nuclear groups on the ventral surface (the gracile and cuneate nuclei) that are the primary relay nuclei for ascending somatosensory information entering the spinal cord. These projection systems continue through the brainstem to synapse in the thalamus en route to the somatosensory cortex. On the ventral surface of the medulla the continuations of the corticospinal motor projections are grouped once again as tight bundles of nerve fibers into the *pyramids*, bilateral bumps on the ventral medulla.

At the level of the medulla these motor axons to the spinal cord cross (forming the pyramidal decussation) in order to project to the contralateral side of the spinal cord; that is, for example, the right-hemisphere motor systems control the left side of the body. At the rostral end of the medulla are large and characteristically formed nuclei of the olivary complex (inferior and medial accessory olivary nuclei). They appear in cross section as highly folded nuclei that are part of the corticocerebellar motor system (Figure 3.29). The olivary nuclei receive inputs from the cortex and red nucleus and project them to the cerebellum. Sensory nuclei that carry out vestibular processing (caudal portions of the vestibular nuclei) and some sensory inputs from the face, mouth, throat (including taste), and abdomen are in the medulla. The medulla also contains motor nuclei that innervate the heart and muscles of the neck, tongue, and throat.

In sum, the brainstem's neurons carry out numerous sensory and motor processes, especially visuomotor, auditory, and vestibular functions, and sensation and



**Figure 3.29** Lateral view of the brainstem showing the midbrain, medulla, and spinal cord. Section is through the medulla at the level of the inferior olivary nucleus.

motor control of the face, mouth, throat, respiratory system, and heart. The brainstem houses fibers that pass from the cortex to the spinal cord and cerebellum, and sensory fibers from spinal levels to the thalamus and then the cortex. Many neurochemical systems have nuclei in the brainstem that project widely to the cerebral cortex, limbic system, thalamus, and hypothalamus.

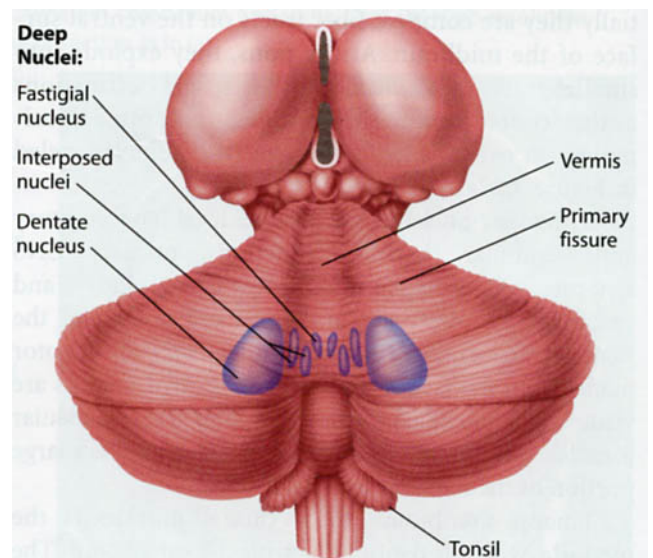
## Cerebellum

The **cerebellum** (literally “small cerebrum” or “little brain”) is actually a very large neuronal structure overlying the brainstem at the level of the pons (see Figure 3.27). It forms the roof of the fourth ventricle and sits on the cerebellar *peduncles* (meaning “feet”), which are massive input and output fiber tracts of the cerebellum (Figure 3.29, left). The cerebellum has several gross subdivisions, including the cerebellar cortex, the four pairs of deep nuclei, and the internal white matter (Figure 3.30). In this way the cerebellum resembles the forebrain’s cerebral hemispheres. The cerebellum is packed with cells; current estimates suggest that the cerebellum contains as many neurons as the rest of the central nervous system combined—about 11 billion!

Although some inputs to the cerebellum terminate in the deep nuclei, the majority of the fibers project to the cerebellar cortex. These inputs come from the parts of the brain that participate in motor and sensory pro-

cessing; hence, they convey information about motor outputs and about sensory inputs describing body position. Inputs from vestibular projections involved in balance, as well as auditory and visual inputs, also project to the cerebellum from the brainstem. The output from the cerebellum originates in the deep nuclei. Ascending

**Figure 3.30** Gross anatomy of the cerebellum. Anterior in the brain is at the top, and the spinal cord is toward the bottom (not shown). This dorsal view of the cerebellum shows the underlying deep nuclei in a see-through projection.





output ascend to the thalamus and then to the motor and premotor cortex. Other output projections of nuclei of the brainstem and are in a position to influence descending projections to the spinal cord. The cerebellum is key to maintaining posture, walking, and performing coordinated movements. By itself, the cerebellum does not control movements directly; instead it integrates information about the body and motor commands and modifies motor outflow to effect smooth, coordinated movements. The cerebellum's role in motor control is given more attention in Chapter 7.

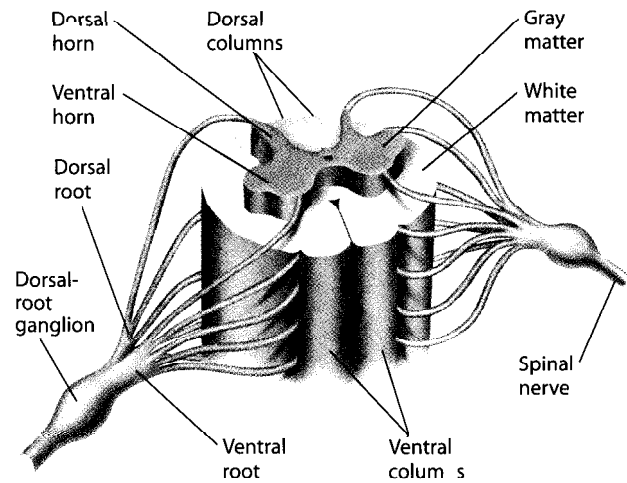
## Spinal Cord

The 'last neural' portion of the CNS to review is the spinal cord, which runs from the medulla to its termination in the *cauda equina* (meaning "horse's tail") at the base of the spine. The spinal cord primarily conducts the final motor signals to muscles; it also takes in sensory information from the body's peripheral sensory receptors and relays it to the brain. In addition, at each level of the spinal cord, reflex pathways exist, as, for example, that for the knee jerk reflex. The gross anatomy of the spinal cord is simple: It consists of white matter tracts carrying sensory and motor information (plus intraspinal projection fibers), and neuronal cell bodies organized in a more central gray matter (Figure 3.31). These include motor neurons, interneurons, and sensory neurons. The gray matter, when viewed in cross section, resembles a butterfly, with two separate sections, or horns, called *dorsal* and *ventral* horns. The ventral horn contains the large motor neurons that project to muscles; the dorsal horn contains sensory neurons and interneurons. The latter project to motor neurons on the same and opposite sides of the spinal cord to aid in the coordination of limb movements.

The spinal cord is protected within the bone of the spine, but with the spine removed, we can view the bilateral pairs of spinal nerves that carry motor output (ventral root) and sensory information (dorsal root) into and out of the spinal cord. These nerves pass through small gaps in the spine.

## Autonomic Nervous System

The **autonomic nervous system** (also called the *autonomic*, or *visceral, motor system*) is part of the PNS and is involved in controlling the action of smooth muscles, the heart, and various glands. It has two subdivisions: the *sympathetic* and *parasympathetic* branches (Figure 3.32). These two systems innervate smooth muscles and glands. The sympathetic system uses the neurotransmit-

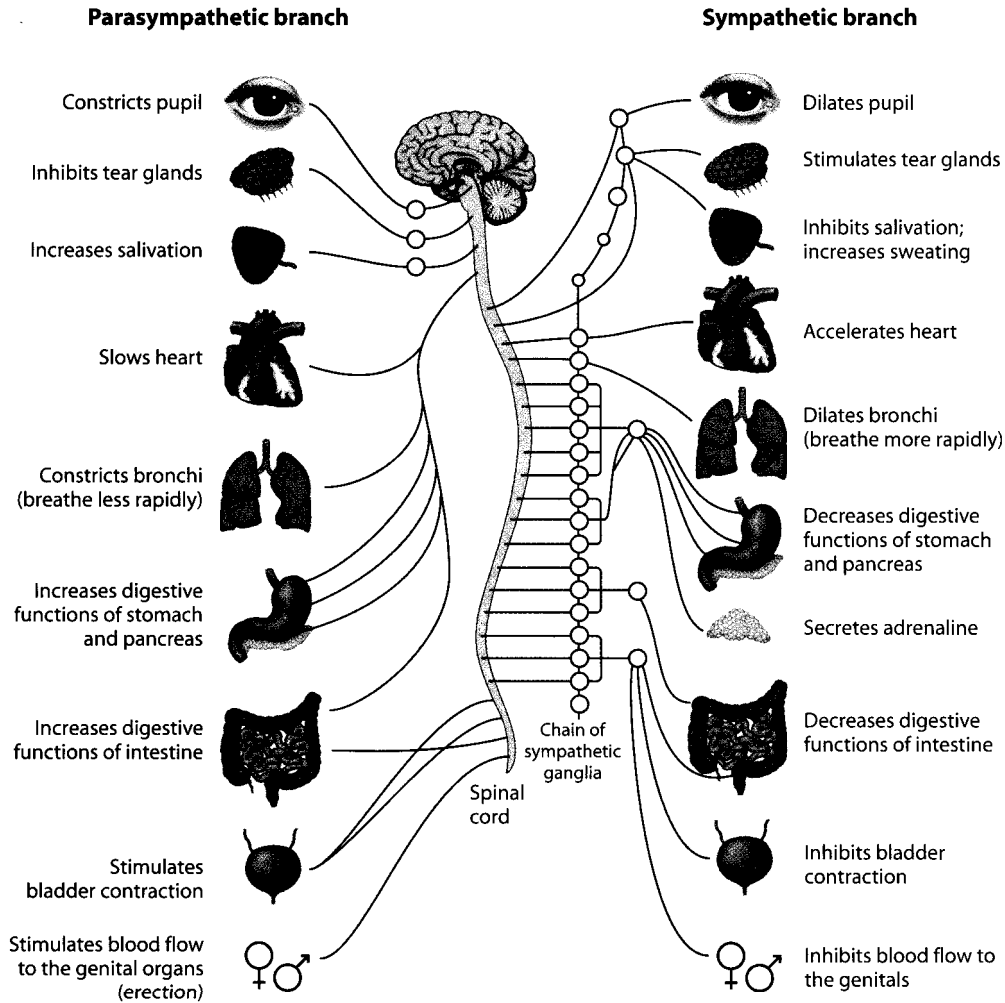


**Figure 3.31** Gross anatomy of the spinal cord. This cross-sectional and three-dimensional representation of the spinal cord shows the central butterfly-shaped gray matter, which contains neurons, and the surrounding white matter tracts, which convey information down the spinal cord from the brain to neurons in the cord and up the spinal cord from peripheral receptors to the brain. The dorsal and ventral nerve roots are shown exiting and entering the cord; they fuse to form peripheral nerves. The cell bodies of peripheral sensory inputs reside in the dorsal-root ganglion and project their axons into the central nervous system via the dorsal root. The ventral horn of the spinal cord houses motor neurons that project their axons out the ventral roots to innervate peripheral muscles.

ter norepinephrine, and the parasympathetic system uses acetylcholine as the transmitter. The two systems frequently operate in an antagonistic manner. For example, activation of the sympathetic system increases heart rate, diverts blood from the digestive tract to the somatic musculature, and prepares the body for action (fight or flight) by stimulating the adrenal glands to release adrenaline. In contrast, activation of the parasympathetic system slows heart rate, stimulates digestion, and in general helps the body with normal functions germane to maintaining the body.

There is a great deal of specialization in the autonomic system that is beyond the scope of this chapter, but understanding that the autonomic system is involved in a variety of reflex and involuntary behaviors is useful for interpreting information presented later in the book. In Chapter 9 we will discuss arousal of the autonomic nervous system and the way in which changes in a number of psychophysiological measures tap into emotion-related changes in the autonomic nervous system. One example is the change in skin conductance that is related to sweat gland activity; sweat glands are under the control of the autonomic nervous system.





**Figure 3.32** Organization of the autonomic nervous system, showing sympathetic and parasympathetic branches.

## DEVELOPMENT OF THE NERVOUS SYSTEM

Thus far we have been discussing the neuroanatomy of the developed adult brain. In humans and many other species, the fetal brain is well developed and shows cortical layers, neuronal connectivity, and myelination; in short, it is already extremely complex. To find out how this complex brain develops prenatally and to uncover the rules governing development, let's examine the development of the nervous system with special reference to the neocortex.

Animal models, such as the rhesus monkey, have permitted a close look at how neurons in the cortex achieve their final connectivity with each other and other brain systems. The monkey has a large cortex and well-developed perceptual and motor skills. Although the human brain is larger in volume and has a larger proportion of association cortex than most other mammals have (Figure 3.33 on p. 90), other animals have provided data important for determining the mecha-

nisms of cortical development, which we would not be able to discover by observing only humans. In recent decades, a wealth of information has been derived about the cellular, biochemical, and hormonal influences on the genesis of the cerebral cortex. New and sophisticated methods permit us to do more than merely observe the changes in the developing brain. They provide us with the chance to manipulate the course of development in ways that inform us about the underlying processes. For example, anatomists have developed tracers that target developing cells and can apply genetic manipulations to observe resultant changes in neurodevelopment.

## Overview of Gross Development

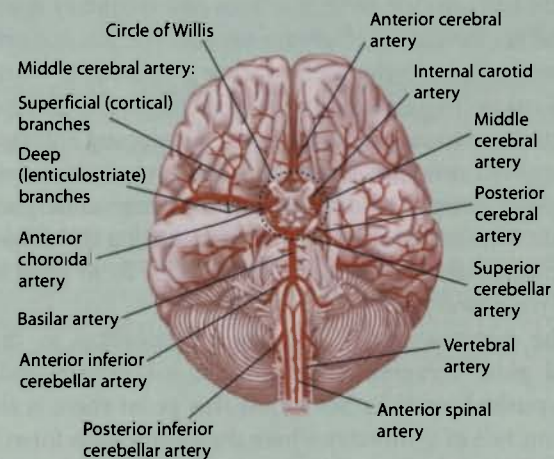
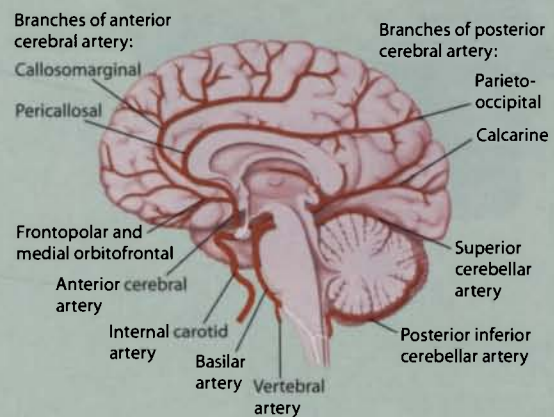
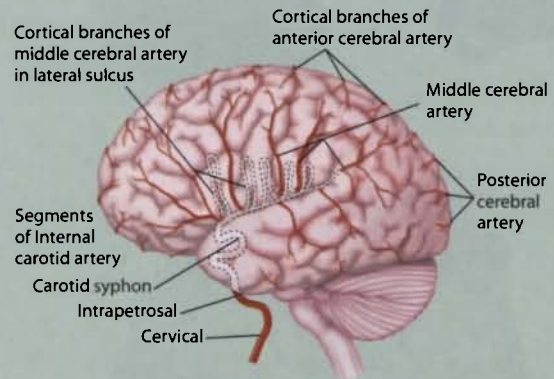
From a single fertilized egg, an organism of billions of cells with specialized functions will arise. This complexity

## HOW THE BRAIN WORKS

## Blood Supply and the Brain

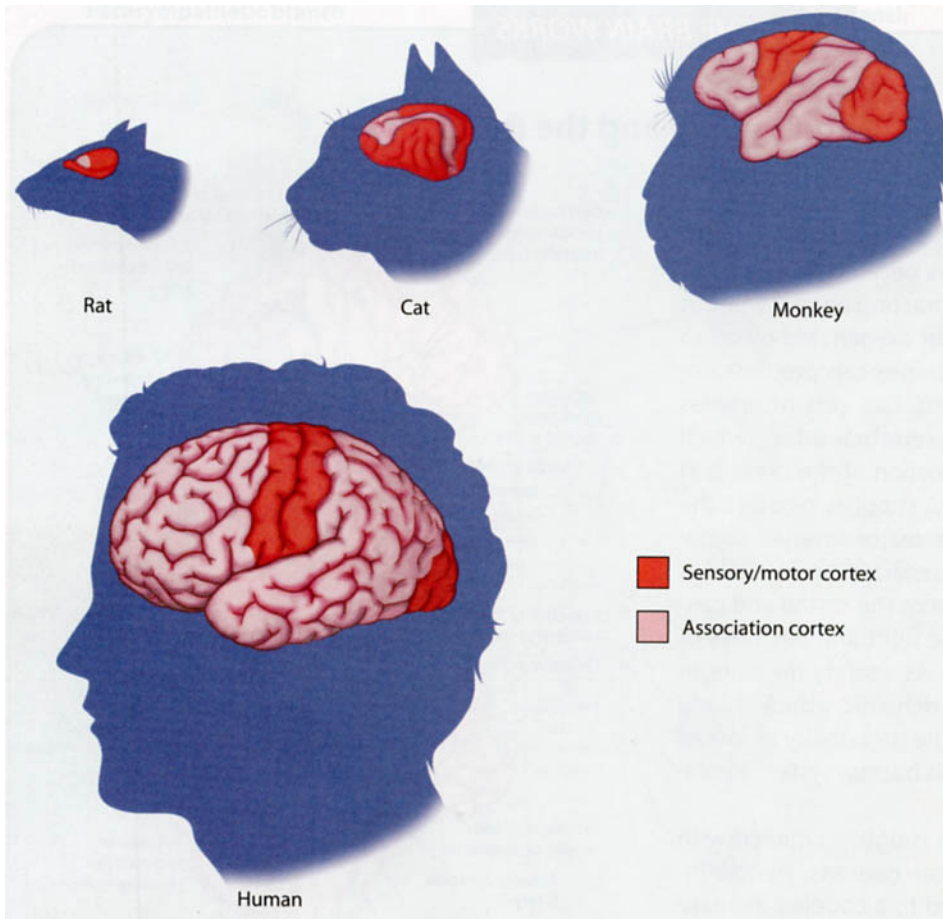
Approximately 20% of the blood flowing from the heart is pumped to the brain. A constant flow of blood is necessary because the brain has no way of storing glucose or extracting energy without oxygen. Disruption in the flow of oxygenated blood to the brain lasting only a few minutes can produce unconsciousness and, finally, death. Two sets of arteries bring blood to the brain: the vertebral artery, which supplies blood to the caudal portion of the brain, and the internal carotid artery, which supplies blood to the rostral portions. Although the major arteries sometimes join together and then separate again, there is actually little mixing of blood from the rostral and caudal arterial supplies or from the right and left sides of the rostral portion of the brain. As a safety measure, in the event of a blockage or ischemic attack, blood should be rerouted to reduce the probability of loss of blood supply, but in practice this backup system is relatively poor.

The blood flow in the brain is tightly coupled with metabolic demand of the local neurons. Hence, increases in neuronal activity lead to a coupled increase in regional cerebral blood flow. The increased blood flow is not primarily for increasing the delivery of oxygen and glucose to the active tissue, but rather to hasten the removal of the resultant metabolic by-products of the increased neuronal activity. The precise mechanisms, however, remain hotly debated. These local changes in blood flow permit regional cerebral blood flow to be used as a measure of local changes in neuronal activity. This is the principle on which some types of functional neuroimaging are based. Particular examples are positron emission tomography using techniques such as the  $^{15}\text{O}$ -water method, and functional magnetic resonance imaging, which is sensitive to changes in the concentration of oxygenated versus deoxygenated blood in the region of active tissue.



clearly peaks in the nervous system. Figure 3.34 on p. 91 depicts a few stages of human development between fertilization and birth. Following fertilization, events lead to the multicellular *blastula* that has already begun to spe-

cialize. The blastula contains three main types of cell lines: the **ectoderm**, the **mesoderm**, and the **endoderm**. In a broad sense, these cell lines form, respectively, (a) the nervous system and the outer skin, lens of the eye, inner



**Figure 3.33** As mammalian evolutionary development progresses from rat to cat to monkey to human, the brain (especially the neocortex) increases in size, association cortex is expanded, and fissures are more prevalent, allowing for greater cortical surface.

ear, and hair; (b) the skeletal system and voluntary muscle; and (c) the gut and digestive organs. The blastula undergoes further development during gastrulation, when invagination (tissue infolding) and cell migration prompt the ectoderm to surround the entire developing embryo. The embryo now has mesoderm and endoderm layers segregated dorsally and ventrally, and then undergoes *neurulation*, as shown in Figure 3.35. During this stage, the ectodermal cells on the dorsal surface form what is called the *neural plate*.

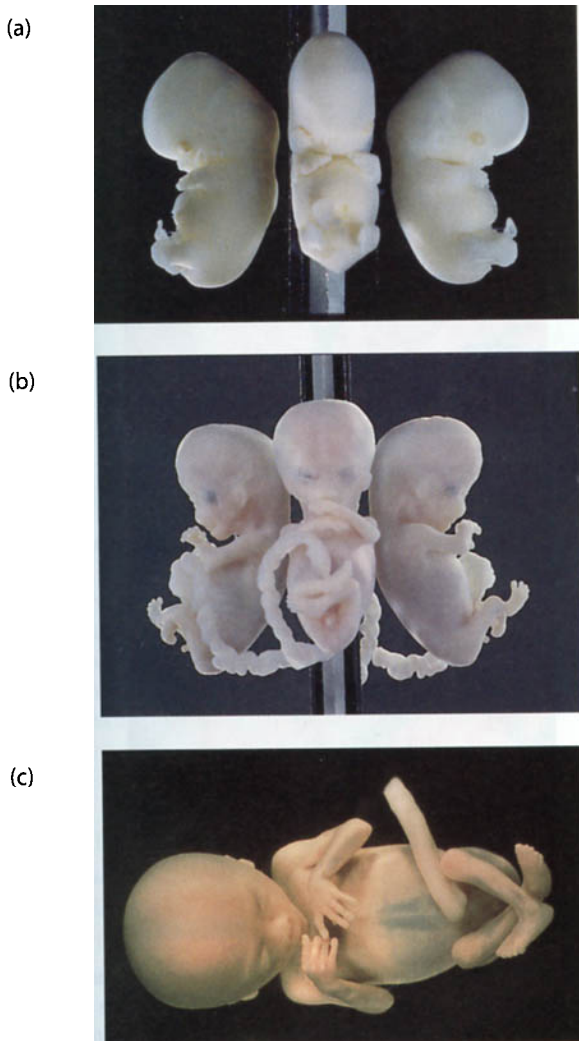
The nervous system continues to develop as the neural plate invaginates, or infolds, via neural folds being pushed up at its border. At this point there is already an axis of symmetry where the neural folds form a groove, the *neural groove*. As this groove deepens, the cells of the neural fold region eventually meet and fuse, forming the *neural tube* that runs anteriorly and posteriorly along the embryo. The adjacent nonneural ectoderm then reunites to seal the neural tube within an ectodermal covering that surrounds the embryo. At both ends of the neural tube are openings (the anterior and the posterior

neuropores) that eventually close. When the anterior neuropore is sealed, this cavity forms the primitive brain, consisting of three spaces, or ventricles (Figure 3.36a, top, on p. 92). From this stage on, the brain's gross features are formed by growth and flexion (bending) of the neural tube's anterior portions (Figure 3.36a, bottom). The result is a cerebral cortex that envelops the subcortical and brainstem structures. The final three-dimensional relations of the brain's structures are the product of continued cortical enlargement and folding. One interesting feature of the flexions during fetal development is that, at these early stages, there is a striking similarity between fetuses of humans and those of other mammals (Figure 3.36b).

### Genesis of the Cerebral Cortex

Let's consider the mechanisms underlying the brain's growth and connectional specificity: **neuronal proliferation**, **neuronal migration**, **neuronal determination and differentiation**, **synaptogenesis**, and **synapse elimination**. Decades of careful studies in animals and



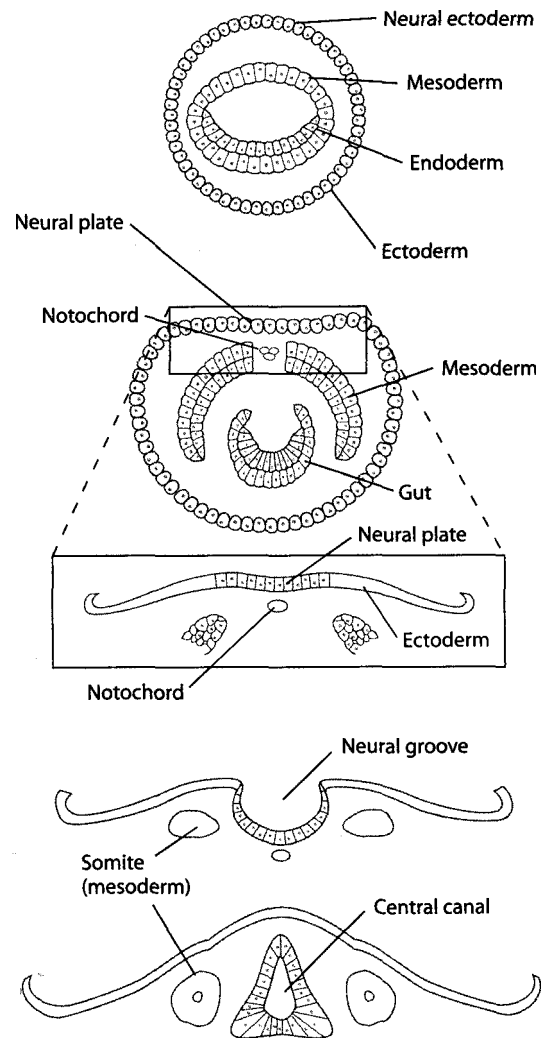


**Figure 3.34** Developing human fetus at 7 weeks (a), 9 weeks (b), and 7 months (c).

humans have provided a relatively detailed understanding of the sequence of these cellular events as they take place on the path to building a mammalian brain.

### NEURONAL PROLIFERATION

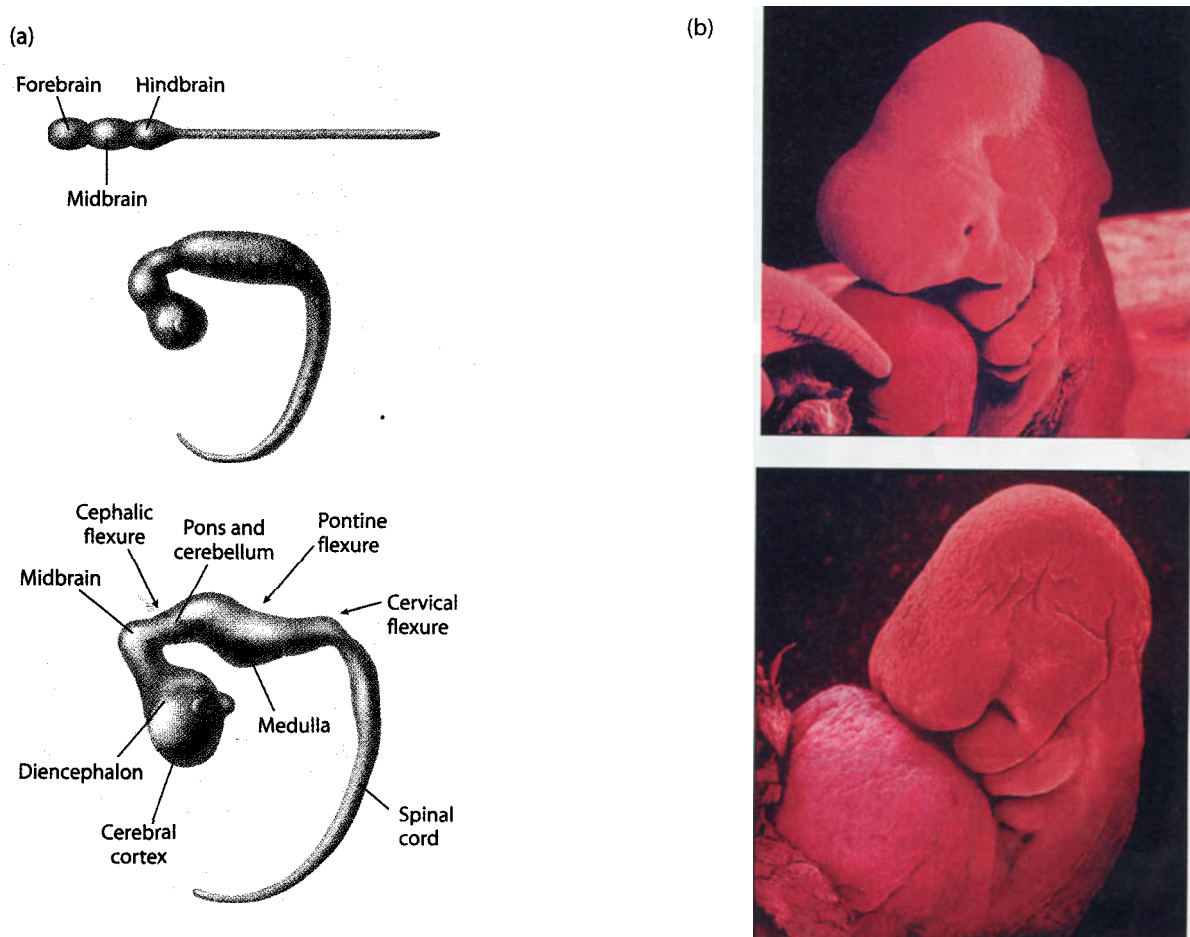
The first question about the brain's development is this: When in the course of prenatal and postnatal development are neurons in the brain "born"? Examination of the brains of newborn monkeys or humans reveals that virtually the entire adult pattern of gross and cellular anatomical features is present at birth. Although axonal myelination continues for some period postnatally (e.g., until adulthood in the human frontal lobe), the newborn has a well-developed cortex that includes the corti-



**Figure 3.35** Development of the vertebrate nervous system. Cross sections through the blastula and embryo at various developmental stages during the first 21 days of life. Early in embryogenesis, the multicellular blastula (**top**) contains cells destined to form various body tissues. Migration and specialization of different cell lines leads to formation of the primitive nervous system around the neural groove and neural tube on the dorsal surface of the embryo. The brain is located at the anterior end of the embryo and is not shown in these more posterior sections, which are taken at the level of the spinal cord.

cal layers and areas characterized in adults. BA17 (the primary visual cortex) can be distinguished from the motor cortex by cytoarchitectonic analysis of its neuronal makeup. Indeed, in primates there is little generation of neurons after birth; almost all neurons are generated prenatally (but see the section titled "Birth of New Neurons Throughout Life" later in this chapter). So





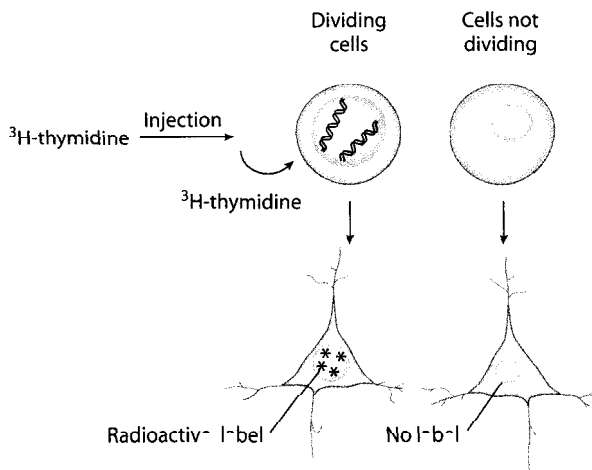
**Figure 3.36** (a) Developing embryo. The embryo goes through a series of folds, or flexures, during development. These alterations in the gross structure of the nervous system give rise to the compact organization of the adult brain and brainstem in which the cerebral cortex overlays the diencephalon and midbrain within the human skull. (b) There is significant similarity between the gross features of the developing fetuses of mammals, as shown by this comparison of human (top) and pig (bottom) fetuses.

the question can be refined like this: When during development can specific types of neurons be identified?

The timeline of neuronal development in nonhuman primates has been tracked by clever cell-labeling methods. The classic anatomical methods are unable to provide this information; by merely staining sections of cortex and observing the neurons present during embryogenesis, we cannot accurately determine which neurons arose first. However, some methods can track cells that are undergoing replication. In *3H-thymidine labeling*, radioactively labeled thymidine is injected into an embryo early in development. The thymidine is taken up by neurons and is used to label DNA in cells undergoing cell division. Because the thymidine is labeled with a radioactive tag, the DNA of only the cells undergoing division at the time of injection will contain

the radioactive label; hence, the label's distribution in the brain tissue can permit us to identify the final fate of the neurons born at the time of injection (Figure 3.37). An *autoradiographic* method is used to determine the distribution of these cells. Sections of brain tissue are placed against photosensitive film, and the radiation exposes the film, creating an image that can be developed and viewed as a picture. The resultant picture shows the distribution within the brain section that contains the  $^3\text{H}$ -thymidine label, and therefore the cells that were born at injection time.

These cell-labeling studies using embryonic tissue make possible a clear view of **corticogenesis**. The genesis of the cerebral cortex in primates begins during the first quarter of gestation and continues for several months. For instance, the production of the neurons of



**Figure 3.37**  $^3\text{H}$ -thymidine method used to determine the fate of neurons that arise at a particular time in prenatal development.  $^3\text{H}$ -thymidine is incorporated into dividing cells and remains within the cell body. The radioactive label can be viewed in the mature neurons and, because the investigator knows when the injection was made, can be used to trace when the neurons arose during development.

BA17 (striate cortex) is not finished until long after the neurons in the other brain areas have been born. Nevertheless, in primates the middle third of the gestational period accounts for the production of all cortical neurons present at birth. The same timeline does not apply

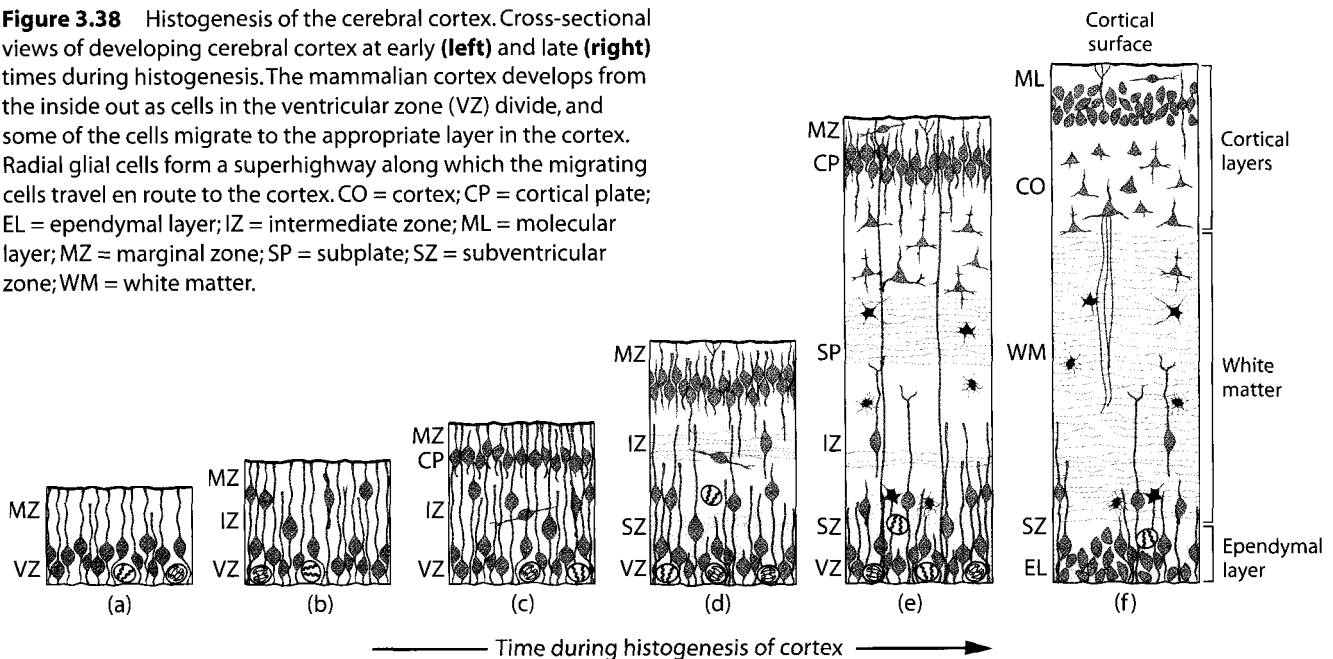
to other mammalian species. In mice and rats, for example, all cortical neurons arise during 1 week of the last third of gestation, and in other species neuronal genesis may continue until after birth.

### NEURONAL MIGRATION

The neurons that form the cortex arise from a layer of cells located adjacent to the ventricles of the developing brain. This layer, known as the *ventricular zone*, has cells that divide to form cortical neurons. Figure 3.38 shows a cross section through the cortex and the precursor cell layers at various times during gestation. **Precursor cells** are undifferentiated cells from which neurons or glial cells are produced; those for neurons and glial cells coexist in the ventricular zone. After these cells undergo mitosis, they migrate outward from the ventricular zone by moving along a peculiar cell known as the **radial glial cell** and described by Ramón y Cajal at the end of the 19th century (see Chapter 1). These cells stretch from the ventricular zone to the surface of the developing cortex. The work of radial glial cells does not end with development. These cells are transformed into astrocytes in the adult brain, helping to form part of the blood–brain barrier.

The migrating neuron remains in contact with the framework provided by the radial glial cell via interactions of cell surface molecules that keep the two cells intimately associated. The movement of the migrating cells is believed to result from contractions of skeletal-

**Figure 3.38** Histogenesis of the cerebral cortex. Cross-sectional views of developing cerebral cortex at early (**left**) and late (**right**) times during histogenesis. The mammalian cortex develops from the inside out as cells in the ventricular zone (VZ) divide, and some of the cells migrate to the appropriate layer in the cortex. Radial glial cells form a superhighway along which the migrating cells travel en route to the cortex. CO = cortex; CP = cortical plate; EL = ependymal layer; IZ = intermediate zone; ML = molecular layer; MZ = marginal zone; SP = subplate; SZ = subventricular zone; WM = white matter.



like intracellular molecules initiated by signals conducted across the membrane via ion channels.

Once the first migrating neurons approach the surface of the developing cortex—a point known as the *cortical plate*—they stop short of the surface. Neurons that migrate later pass beyond the termination point of the initial neurons and end up in more superficial positions—positions nearer the outer cortical surface. Thus, it is said that the cortex is built from the inside out because the first neurons to migrate lie in the deepest cortical layers, whereas the last to migrate move farthest out toward the cortical surface. This timeline of cortical cell genesis has been demonstrated with the thymidine-labeling method, as in Figure 3.39.

Early in corticogenesis, injection of radioactive thymidine leads to labeling of neurons in the deepest cortical layers, V and VI, and the underlying white matter, whereas at later stages of corticogenesis, injections of radioactive thymidine label neurons in more superficial cortical layers: II and I. As noted earlier, the timeline of cortical neurogenesis differs across cortical cytoarchitectonic areas, but the inside-out pattern is the same for all cortical areas. Because the timeline of cortical neurogenesis determines the ultimate pattern of cortical lamination, anything that affects the genesis of cortical neurons will lead to an ill-constructed cortex. A good example of how neuronal migration can be disrupted in humans is *fetal alcohol syndrome*. In cases of chronic maternal alcohol abuse, neuronal migration is severely disrupted and results in a disordered cortex, and a consequent plethora of cognitive, emotional, and physical disabilities.

### NEURONAL DETERMINATION AND DIFFERENTIATION

So far we have regarded the cells in the ventricular zone as a single population. But how does this population of virtually identical precursor cells give rise to the variety of neurons in the adult cortex? Moreover, where do the glial cells come from? The answers to these questions are known: All cortical cells, including neuronal subtypes and glial cells, arise from the precursor cells of the ventricular zone through cell division and differentiation.

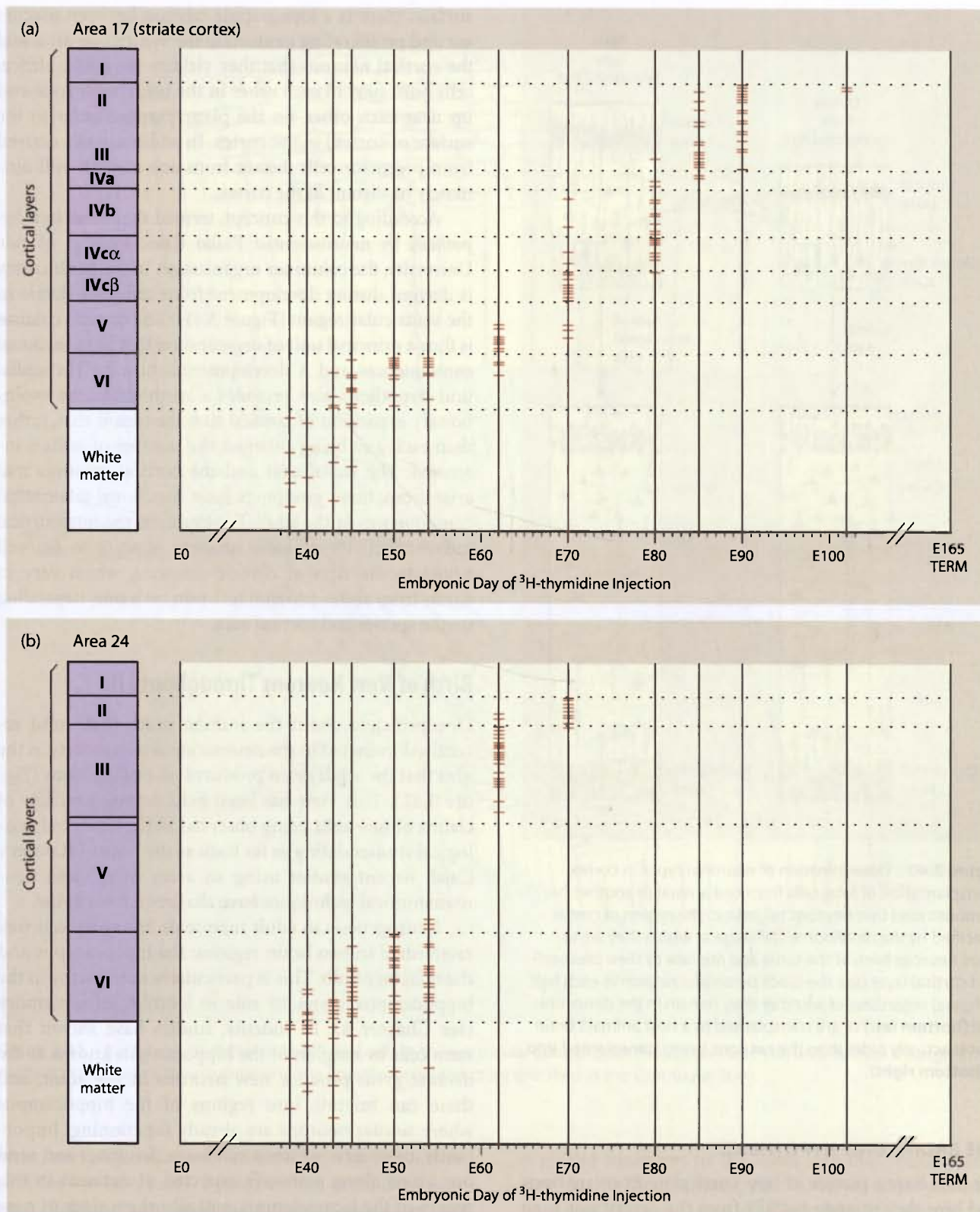
For the first 5 to 6 weeks of gestation, the cells in the ventricular zone divide in a symmetrical fashion. The result is an exponential growth in the number of precursor cells. After this time, though, asymmetrical division begins and one of the two cells present after division becomes a migratory cell. The other remains in the ventricular zone and continues to divide. This subsequent division is also asymmetrical, yielding one remaining and one migratory cell. This process contributes the cells mi-

grating to cortical layers. In later gestational periods, the proportion of cells that migrate increases until eventually the final state yields a laminar cortex, with an epithelial layer that becomes the cell lining of the ventricles known as the *ependymal cell layer*.

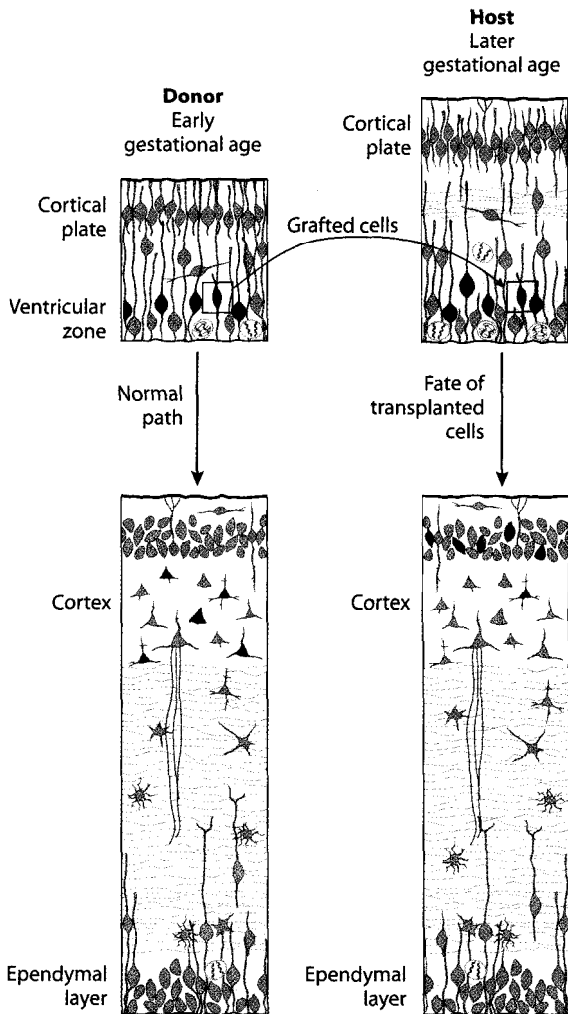
The cortex is made up of many different types of neurons, and these are organized in a laminar fashion. Layer IV, for example, contains large pyramidal cells, layer III is populated primarily by stellate cells, and so on. The neuronal type of a migrating neuron is determined at the point of cell division. Experimental manipulations have shown that the time of neurogenesis is a key determinant of which cell type develops; the type is not hardwired into the code of each developing neuron. Neurons that are supposed to migrate but have been prevented from doing so by experimental intervention, such as exposure to high-energy X-rays, eventually form cell types and patterns of connectivity that would be expected from neurons that are created at the same gestational stage. Even though these neurons might remain in the ventricular zone, they display interconnections with other neurons that would be normal had they migrated to the cortical layers.

Similar evidence comes from transplanting cells from one animal to another. If embryonic cells from the ventricular region are removed at a certain stage of gestation and transplanted to the cortex of newborn host animals, such as ferrets, these transplanted neurons migrate to the proper cortical layer expected for their gestational age, regardless of the time during gestation at which the host tissue receives the graft (Figure 3.40). Again, we see here evidence that it is the time of genesis of the cell, not the time of migration, that is key. Even if the host cortex is past the stage when neurons migrate to layers V and VI—for example, when the neurons in the host are migrating past these layers to form layers II and III—a transplanted neuron whose gestational age dictated that it should migrate to layers V and VI will indeed move to these layers. What's more, these transplanted neurons take on the morphological form (i.e., stellate cell, pyramidal cell, etc.) and the connectional pattern predicted by their age; that is, they are predetermined to be a certain neuronal type. The alternative would have been to have the properties (morphology, connectivity, biochemistry, etc.) of each cortical neuron determined by the neuronal environment where they reside, as with cells that form the neuronal and glial cells of the peripheral sensory systems and the autonomic nervous system. For mammalian cortical neurons, neuronal properties are specified long before the migrating neuron reaches its destination in the cortex.





**Figure 3.39** Birth ages of cortical neurons. Radiolabeled thymidine was used to label cells at different embryonic days in two cortical areas: (a) BA17 and (b) BA24. The cortical layers present at birth are shown on the axis at the left, with the cortical surface at the top of each plot. Cells with birth dates later in gestation are found in more superficial cortical layers, but the time course of this development differs for different cortical regions.



**Figure 3.40** Determination of neuronal types in cortex. Transplantation of fetal cells from one animal to another has demonstrated that neurons migrate to the region of cortex specified by the developmental stage at which they arose. Thus, neurons born at the same age migrate to their prespecified cortical layer (see the black pyramidal neuron in each half of figure) regardless of whether they remain in the donor animal (**bottom left**) or are transplanted to a host animal's brain that is actually older than the neurons being transplanted into it (**bottom right**).

### THE RADIAL UNIT HYPOTHESIS

We now have a picture of how cortical neurons are born and how they migrate radially from the ventricular zone toward the surface of the developing cortex. The neurons migrate along the radial glial cells that form a pathway for them. Because the radial glial highway is organized in a straight line from the ventricular zone to the cortical

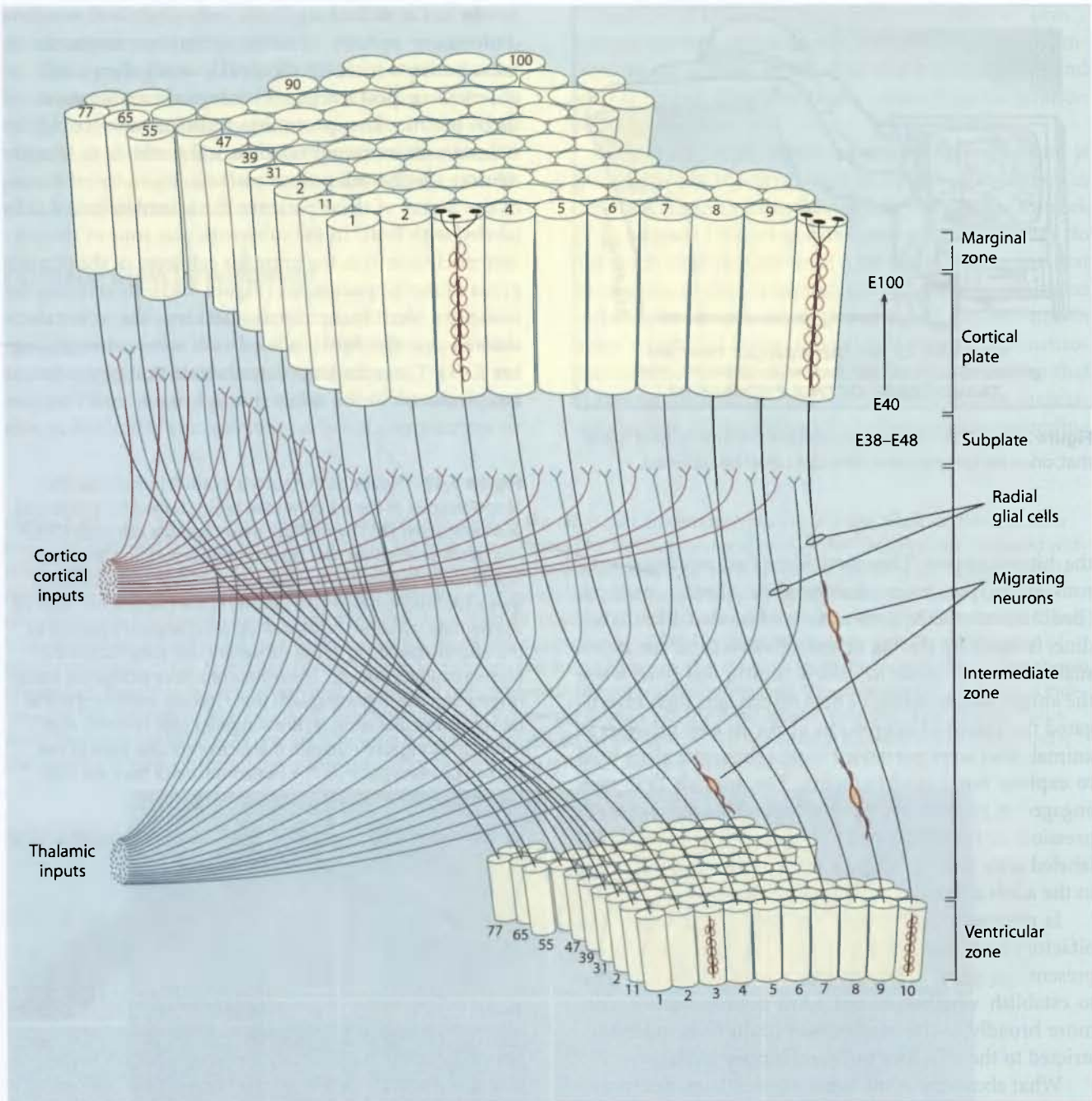
surface, there is a topographic relation between precursor and proliferating neurons in the ventricular area, and the cortical neurons that they yield in the adult. Hence, cells born next to each other in the ventricular zone end up near each other (in the plane perpendicular to the surface of cortex) in the cortex. In addition, cells derived from precursor cells disperse from one another ultimately be distant in the cortex.

According to this concept, termed the *radial unit hypothesis* by neuroscientist Pasko Rakic (1995a) of Yale University, the columnar organization in the adult cortex is derived during development from cell birth order in the ventricular region (Figure 3.41). The cortical column is thus a principal unit of organization that has functional consequences and a developmental history. The radial unit hypothesis also provides a method for the evolutionary expansion of cortical size; the idea is that, rather than each unit being enlarged, the number of units is increased. The radial unit and the cortical column arise from these groupings have functional-anatomical consequences in the adult. For example, the intracortical interconnectivity of local neurons appears to be well suited to the sizes of cortical columns, which vary in adults from about 100  $\mu\text{m}$  to 1 mm on a side, depending on the species and cortical area.

### Birth of New Neurons Throughout Life

One principle about the human brain that, until recently, dominated in the neuroscience community, is the idea that the adult brain produces no new neurons (Figure 3.42). This view has been held despite a variety of claims of new cells being observed in the brain in histological studies dating as far back as the time of Ramón y Cajal. Recent studies using an array of modern neuroanatomical techniques have challenged this belief.

Neurogenesis in adult mammals has now been well established in two brain regions: the hippocampus and the olfactory bulb. This is particularly noteworthy in the hippocampus, given its role in learning and memory (see Chapter 8). In rodents, studies have shown that stem cells in a region of the hippocampus known as the *dentate gyrus* produce new neurons in the adult, and these can migrate into regions of the hippocampus where similar neurons are already functioning. Importantly, these new neurons can form dendrites and send out axons along pathways expected of neurons in this region of the hippocampus, and also show signs of normal synaptic activity. These findings are particularly interesting because the number of new neurons correlates positively with learning or enriched experience (more social contact or challenges in the physical environ-




**Figure 3.41** Radial unit hypothesis. Radial glial cells in the ventricular zone project their processes in an orderly map through the various cortical layers, thus maintaining the organizational structure specified in the ventricular layer.

ment) and negatively with stress (e.g., living in an overcrowded environment). Moreover, the number of newborn neurons is related to hippocampus-dependent memory (Shors, 2004).

A key remaining question is the extent to which these new neurons become integrated into functional networks of neurons to participate in behavioral and

cognitive functions in the same way that those generated during development do. To answer this question, Fred Gage in San Diego, Carol Barnes in Arizona, and their colleagues (Ramirez-Amaya et al., 2006), were able to demonstrate that the immediate early gene *Arc* that is expressed in neurons during exploratory behavior in rodents was also expressed in newborn adult neurons in





**Figure 3.42** This cartoon exposes the commonly held belief that, once we lose neurons, they can never be replaced.

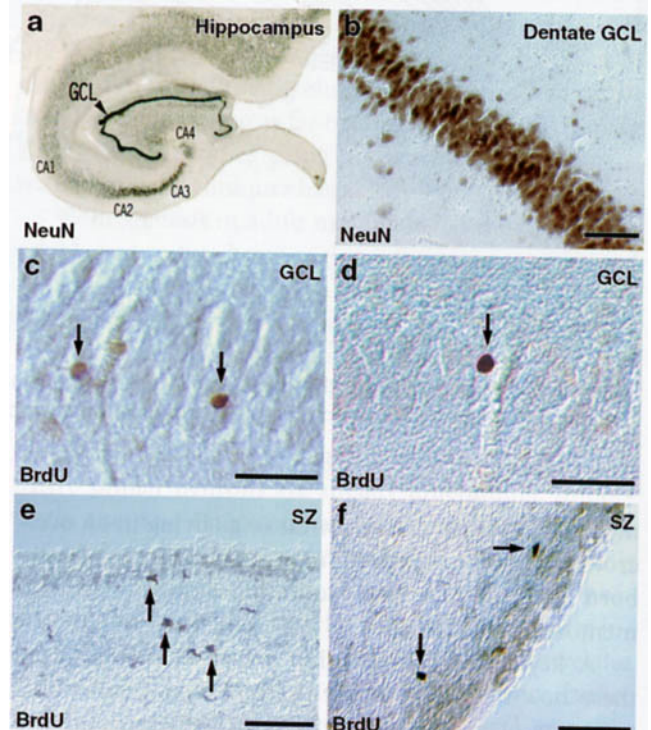
the hippocampus. They first identified newborn neurons using the bromodeoxyuridine (BrdU) method. (BrdU is a synthetic form of thymidine that, like thymidine, is taken up during mitotic division and can be visualized later as evidence that a neuron was born when the animal was an adult.) These researchers then investigated the extent of expression of *Arc* in new neurons in animals that were permitted versus those not permitted to explore novel environments. The animals that were engaged in exploratory behavior showed greater *Arc* expression in those hippocampal neurons that were also labeled with BrdU and therefore were newborn neurons in the adult animals.

Is neurogenesis restricted to the hippocampus and olfactory bulb? The answer remains controversial, but at present it appears to be no. Future work will be required to establish whether or not adult neurogenesis occurs more broadly in the mammalian brain or is indeed restricted to the olfactory bulb and hippocampus.

What about the adult *human* brain? Does neurogenesis also occur in mature humans? In a fascinating line of research, a team of scientists from California and Sweden (Eriksson et al., 1998) used very similar methods to explore this question in a group of terminally ill cancer patients. As part of a diagnostic procedure related to their treatment, the patients were given BrdU, the same synthetic form of thymidine used as a label to identify neurogenesis in animal studies. The purpose was to assess the extent to which the tumors in the cancer patients were proliferating; tumor cells that were dividing would take up BrdU, and this label could be used to quantify the progress of the disease.

As in the animal studies already described, neurons undergoing mitotic division during neurogenesis in these patients took up the BrdU, which then could be observed in postmortem histological examinations of their brains. The postmortem tissue also could be stained with immunohistochemical methods to identify neuron-specific cell surface markers. Upon investigation of the brains of these patients, the scientists found cells labeled with BrdU in the subventricular zone of the caudate nucleus and in the granular cell layer of the dentate gyrus of the hippocampus (Figure 3.43). By staining the tissue to identify neuronal markers, the researchers showed that the BrdU-labeled cells were neurons (Figure 3.44). These findings demonstrate that new neurons are produced in the adult human brain, and that our

**Figure 3.43** Newly born neurons in adult human. (a) The hippocampus of the adult human brain stained for a neuronal marker (NeuN). (b) The dentate gyrus granule cell layer (GCL) in a NeuN-stained section. (c) Bromodeoxyuridine (BrdU)-labeled nuclei (arrows) in the granule cell layer of the dentate gyrus. (d) BrdU-labeled cells (arrow) in the granule cell layer of the dentate gyrus. (e) BrdU-stained cells (arrows) adjacent to the ependymal lining in the subventricular zone (SZ) of the human caudate nucleus. These neurons have elongated nuclei resembling the migrating cells that typically are found in the rat subventricular zone. (f) BrdU-stained cells (arrows) with round to elongated nuclei in the subventricular zone of the human caudate nucleus. The horizontal black bars are scale bars representing 50  $\mu\text{m}$ .



brains renew themselves throughout life to an extent previously thought not possible.

This exciting line of research holds great promise for the future of neuroscience. Research is under way to investigate the functionality of new neurons in the adult brain and to determine whether or not such neuronal growth can be facilitated in order to ameliorate stroke or diseases such as Alzheimer's.

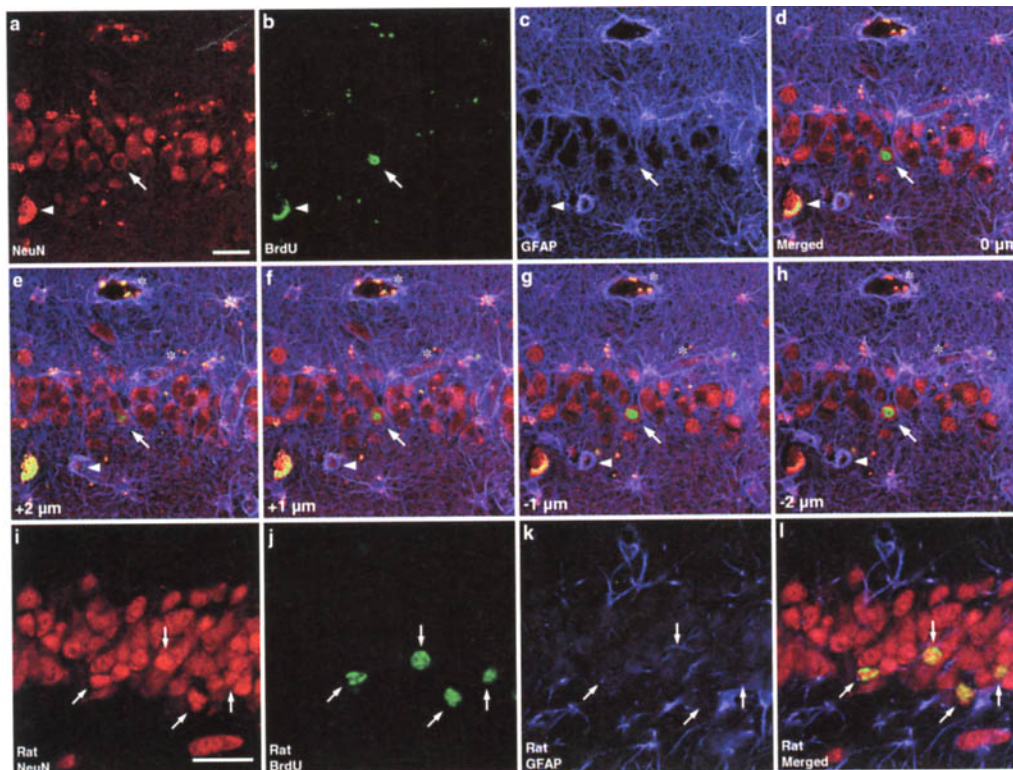
## Postnatal Brain Development

A host of behavioral changes take place during the first months and years of life. What accompanying neurobiological changes enable these developments? Even if we assume that neuronal proliferation continues, we know that, at birth, the human has a fairly full complement of

neurons, and these are organized intricately to form a human nervous system that is normal, even if not complete in all details. What details are incomplete, and what is known about the time course of the maturation of the brain?

One important aspect of neural development is *synaptogenesis*, the formation of synapses. Synapses in the brain begin to form long before birth, prior to week 27 in humans (counting from conception), but they do not reach peak density until after birth, during the first 15 months of life. Synaptogenesis is more pronounced early in the deeper cortical layers and occurs later in more superficial layers, following the pattern of neurogenesis described earlier. At roughly the same time that synaptogenesis occurs, neurons of the brain are increasing the size of their dendritic arborizations, extending

**Figure 3.44** The birth of new neurons in the dentate gyrus of the adult human compared to those in the adult rat. New neurons show simultaneous labeling for different stains. **(a)** A neuron is labeled for NeuN, a neuronal marker. **(b)** The same cell is labeled with BrdU, indicating that it is newly born (full arrow). (Note that the lone arrowheads in (a) through (d) are pointing to neurons that are fluorescing red or green, owing to nonspecific staining; i.e., these are not newly born neurons). **(c)** This same cell is not stained by glial fibrillary acidic protein (GFAP), indicating that it is not an astrocyte. **(d)** The three stained sections are merged. The image shows that a BrdU-labeled cell could specifically coexpress NeuN without expressing GFAP. Confocal microscopy permits examination of the coexpression of NeuN and BrdU in the neuron by focusing the image above **(e, f)** and below **(g, h)** the level of the section shown in panel (d). Note that red blood cells and endothelial cells, present in several small blood vessels, show nonspecific staining, as indicated by the asterisks in (e) through (h). Panels **(i)** through **(l)** show the similarity of the BrdU-labeled neurons in rat dentate gyrus. Note: The scale bar in (a) is 25  $\mu\text{m}$ , and the scale is the same for panels (a) through (h). The scale bar in panel (i) is also 25  $\mu\text{m}$  and is the scale for (i) through (l), but the magnification for (i) through (l) is higher than for (a) through (h).



their axons, and undergoing myelination. Synaptogenesis is followed by synapse elimination (sometimes called *pruning*), which continues for more than a decade. Synapse elimination is a means by which the nervous system fine-tunes neural connectivity, presumably eliminating the interconnections between neurons that are redundant or do not remain functional. An example comes from primary visual cortex (BA17), where there is initially more overlap between the projections of the two eyes onto neurons in BA17 than there is when synapse elimination is complete. After synapse elimination, the cortical areas within BA17 (*ocular dominance columns*) are nearly completely segregated with regard to the eye from which the projections are received.

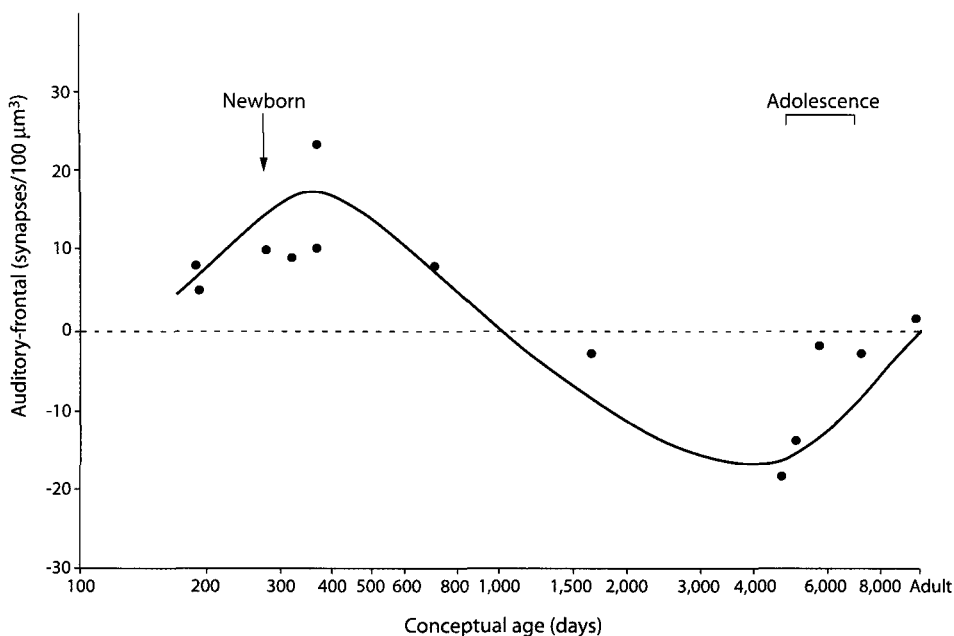
One of the central hypotheses about the process of human synaptogenesis and synapse elimination is that the time course of these events differs in different cortical regions. By contrast, in the brain development of other primates, synaptogenesis and pruning appear to occur at the same rates across different cortical regions. However, differences in methodology must be resolved before these interspecies variations will be wholly accepted. Nonetheless, compelling evidence suggests that different regions of the human brain reach maturity at different times.

Peter Huttenlocher and his colleagues (e.g., Huttenlocher & Dabholkar, 1997) at the University of Chicago investigated the time course of synaptogenesis in auditory cortex and prefrontal cortex (middle frontal gyrus)

in postmortem human brains ranging in age from 28 weeks after conception (one premature infant) to 59 years. They stained the tissue from the two cortical areas using the phosphotungstic acid (PTA) method, which stains proteins associated with synapses, and visualized the stained synapses using electron microscopy so that they could count the number of synapses per unit of cortical volume.

They found that synapses in the superior temporal region, in the auditory cortex, reached peak density earlier in postnatal development (around the age of 3 months) than did synapses in the association cortex of the frontal lobe, the density of which peaked around the age of 15 months. Synapse elimination, which occurs later in life, also appeared to end earlier in the auditory cortex than in the prefrontal cortex, although this finding remains less well established. The general pattern is shown in Figure 3.45 as the biphasic plot of the difference between the synaptic density values in the prefrontal cortex and those in the auditory cortex; initially density is greater in the auditory cortex, and later it is greater in the prefrontal cortex. These data suggest that, in humans, synaptogenesis and synapse elimination follow different time courses in sensory (and motor) cortex than in association cortex, like that in the prefrontal cortex.

Measurements of glucose metabolism also can be used in living persons to investigate development of the brain, and a time course similar to that in the foregoing



**Figure 3.45** Plot of the difference score obtained by subtracting the value for synaptic density in the frontal cortex from that for synaptic density in the auditory cortex, as a function of the conceptual age of humans. Prenatal synaptic density peaks earlier for the auditory cortex, as reflected by the positive difference score, and later for the frontal cortex, as reflected by the negative difference score.



has emerged from studies using positron emission tomography (PET) in infants, children, and adolescents. Harry Chugani (1998) of Wayne State University School of Medicine showed that glucose metabolism measured at rest rapidly increases with age in young infants and decreases during the teenage years. In newborns, glucose metabolism is highest in sensory and motor cortical areas, in the hippocampus, and in subcortical areas including the thalamus, brainstem, and cerebellar vermis. By the age of 2 to 3 months, more glucose starts to be used in parietal and temporal cortex, the primary visual cortex, and the basal ganglia and cerebellar hemispheres. Glucose utilization in the frontal cortex increases between the ages of 6 and 12 months. The overall level of glucose use in the developing brain increases until about the age of 4 years, plateaus through about age 10, and decreases gradually to adult levels between the ages of 16 and 18 years. These data argue for a developmental time course in the human brain that is similar to that described in the results of histological methods, such as measures of synaptic density, and therefore reinforce the idea that different regions of the human brain develop at different rates, with association areas lagging behind sensory and motor structures (see Chapter 15 for an evolutionary perspective on cortical development).

Another trend in postnatal development is the significant increase in brain volume during the first 6 years. The increase appears to be the result of both myelination and the proliferation of glial cells. Jay Giedd and his colleagues at the National Institutes of Health, with Tomas Paus and his colleagues at McGill University in Montreal, Canada, calculated growth curves for gray and white matter volume in the lobes of the developing human brain (Giedd et al., 1999). The research team used magnetic resonance images to quantify white and gray matter volumes in children and young adults (ages between 4 and 20) who were willing to be scanned multiple times over a few different years.

The researchers found that white matter volume increased linearly with age and that the time course was not different for different cortical regions. In contrast, gray matter volume increased nonlinearly, showing a preadolescent increase followed by a postadolescent decrease—a finding in accord with the results from PET studies and postmortem histological measures. In addition, the time courses of the gray matter increases and decreases were not the same across different cortical regions. In general, these data support the idea that postnatal developmental changes in the cerebral cortex may not occur with the same time course across all cortical regions (see also Shaw et al., 2006).

## PLASTICITY IN THE NERVOUS SYSTEM

It is obvious from the dramatic cellular events that occur during gestation that the nervous system is tremendously **plastic**, or adaptive, during development. It can change its form, including the type and location of cells and how they are interconnected. This developmental plasticity stands in stark contrast to the relative rigidity of the adult brain. Indeed, until recently it was widely believed that the adult brain was incapable of great change.

However, it is now abundantly clear that plasticity does exist in the adult brain. After all, we learn new things even as adults, and these new skills must be reflected in the anatomy of our brains. Learning involves primarily changes in the synaptic strength between neurons in the brain's circuitry. As we learn, connections that are critical to the learned action or behavior are strengthened, while those that are not used are weakened. The mechanisms underlying such changes are beginning to be understood in great detail at the molecular level (e.g., see the discussion of long-term potentiation in Chapter 8). So there must be some plastic

change in the adult brain, given the fantastic behavioral plasticity that adults display.

### Cortical Maps and Experience

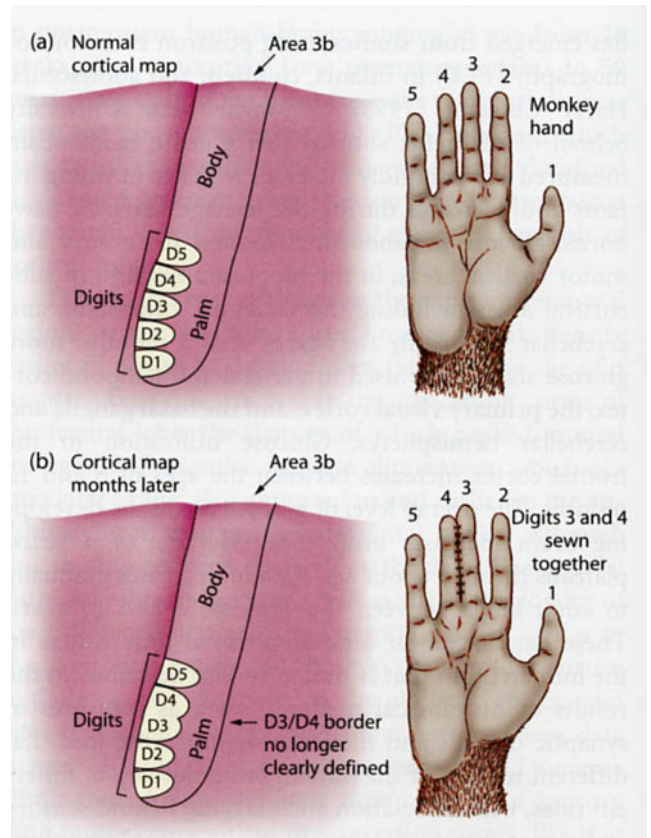
Since the mid 1980s an amazing revolution in neuroscience has grown out of the work of Michael Merzenich (Merzenich & Jenkins, 1995; Merzenich et al., 1988) at the University of California, San Francisco; and Jon Kaas (1995) at Vanderbilt University. These scientists have investigated how sensory and motor maps (called *homunculi*; see “How the Brain Works: Cortical Topography,” on p. 74) in the cortex can be modified with experience. The organization of the body is reflected in the cortical representation of the body—a principle known as **topography**. For example, within somatosensory cortex, neurons that respond to touch of the index finger are adjacent to those that respond to touch of the middle finger, which are also neighbored by neurons that respond to touch of the ring finger. Similarly, the hand area as a whole is adjacent to the lower

arm area, which is near the upper arm, and so forth. This mapping of specific parts of the body to areas of the cortex is known as **somatotopy**, resulting in somatotopic maps of the cortical areas. It is interesting to ask why such maps exist, since there is no inherent necessity for the organization. Yet topographic maps are a common feature of the nervous system (see Chapter 5), perhaps reflecting the fact that neighboring body parts are frequently co-recruited, as when we're gripping a ball or stroking a favorite pet.

Merzenich and Kaas discovered that the size and shape of these maps can be altered by experience, even in adult animals. Radical manipulation might involve amputating a digit, cutting the nerves that innervate a limb, or sewing together two fingers of one hand so that they always move in a perfectly synchronized manner. A less radical approach might be to apply a specific stimulus over and over to only one finger. With all of these manipulations, significant changes in the somatotopic maps have been observed. For example, when a finger of a monkey is deafferented—that is, the nerve fibers from that finger to the spinal cord are severed—the relevant part of the cortex no longer responds to the touch of that finger (Figure 3.46). This is perhaps no big surprise; after all, the cortex is no longer receiving input from that finger. But here comes the strange part: The area of the cortex that formerly represented the denervated finger soon becomes active again and responds to stimulation of the finger adjacent to the amputated finger. The surrounding cortical area fills in the silent area and takes over. Similar changes are found with less invasive procedures, such as when a particular finger is given extended sensory stimulation. This functional plasticity suggests that the adult cortex is a dynamic place where changes can still happen. Such phenomena demonstrate a remarkable plasticity.

Are phenomena of cortical functional plasticity limited to monkeys, or do humans also display such cortical plasticity? Professor Vilayanur Ramachandran at the University of California, San Diego, studied the cortical mapping of human amputees and brought the dramatic animal results into the realm of human phenomena. Consider the human cortical somatosensory surface. Starting at one point, the pharynx is represented, then the face, with the sensitive lips having a huge area of representation, and next to the face are the fingers and hand, followed by the arm and leg (Figure 3.47).

Ramachandran reasoned that a cortical rearrangement ought to take place if an arm is amputated, just as had been found for the amputation of a digit in monkeys. Such a rearrangement might be expected to create bizarre patterns of perception. Remember that the face

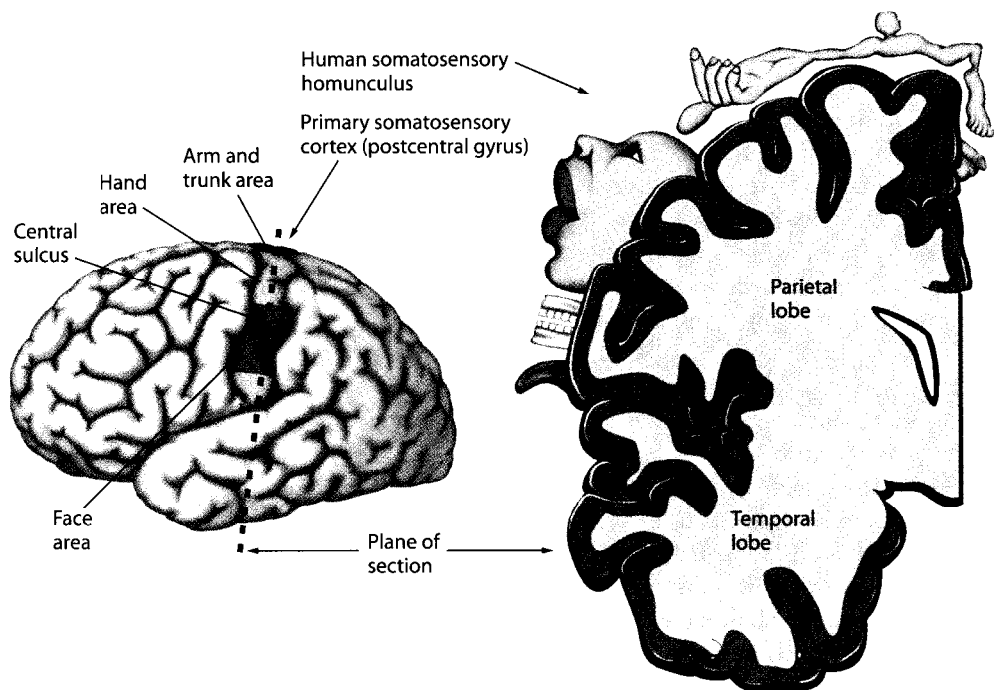


**Figure 3.46** Reorganization of sensory maps in the primate cortex. **(a)** In a mapping of the somatosensory hand area in normal monkey cortex, the individual digit representations can be revealed by single-unit recording. **(b)** If the two fingers of one hand are sewn together, months later the cortical maps change such that the sharp border once present between the sewn fingers is now blurred.

area is next to the hand and arm area—an important point for understanding this story. Suppose there were no lower arm or hand to send sensory signals to the brain. According to animal research, the region coding for the arm that had been amputated might become functionally innervated by the surrounding cortex. That is exactly what happened in several spectacular cases.

In one case, Ramachandran studied a young man who had recently had his arm amputated just above the elbow. About 4 weeks after the amputation, the young man was tested. When a cotton swab was brushed lightly against his face, he reported feeling his amputated hand being touched! Feelings of sensation in missing limbs are the well-known phenomenon of *phantom limb sensation*; however, this case is different because the sensation was introduced by stimulating the face. Indeed, with careful examination, a map of his hand could be demonstrated on his face (Figure 3.48)!

**Figure 3.47** Human somatosensory homunculus. The representation of the body surface is mapped in a somatotopic fashion onto the somatosensory cortex of the parietal lobe. At right is a coronal view of the left hemisphere showing the approximate location and relative cortical area (as indicated by distorted sizes of various body parts) dedicated to body parts. The anterior–posterior plane of the coronal section is

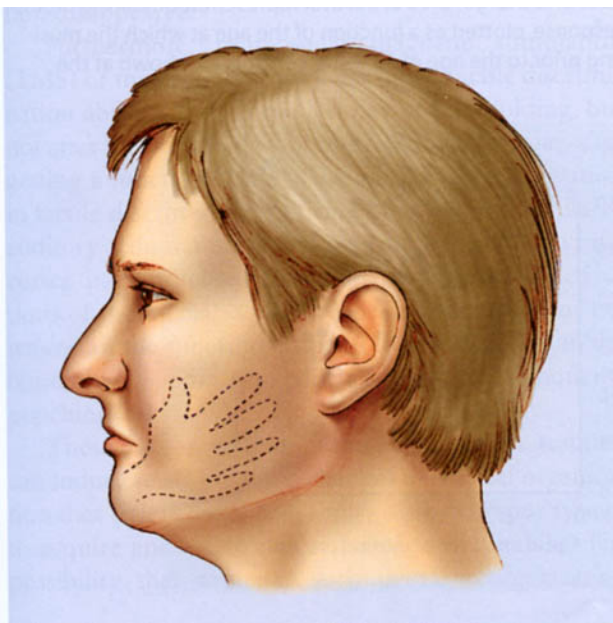


Ramachandran's (1993) report of another case is too good not to quote verbatim:

A neuroscience graduate student wrote to us that soon after her left lower leg was amputated she found that sensation in her phantom foot was enhanced in certain situa-

tions—especially during sexual intercourse and defecation. Similarly an engineer in Florida reported a heightening of sensation in his phantom (left) lower limb during orgasm and that his experience . . . actually spread all the way down into the [phantom] foot instead of remaining confined to the genitals: so that the orgasm was much bigger than it used to be. (p. 10417)

**Figure 3.48** Hand representation sketched on the face of the amputee studied by Ramachandran.



These are dramatic examples of plasticity in humans following significant injury or altered experience. But is there evidence that changes in experience within the normal range—say, due to training—have any ability to influence the organization of the adult human brain?

### Plasticity in the Adult Human Brain

We have learned that the brains of adult mammals, including humans, generate new functioning neurons. We have also seen that the organization of the sensory systems can be dramatically altered following injury or damage. Given these facts, we might well expect to see changes in adult human brains as the result of significant training, as, for example, in the acquisition and maintenance of musical skill.

Thomas Elbert and his colleagues at the University of Konstanz used magnetoencephalography (MEG) to investigate the somatosensory representations of the hand area in musicians, specifically violin players (Elbert et al., 1995). Recall that violinists use the right hand



to operate the bow and the left hand to finger the strings. Stimulating the fingers with a precisely controlled device that touches the skin showed that the responses in the right hemisphere (which controls the left fingers that manipulate the violin strings) of the musicians were larger than those observed in nonmusicians (Figure 3.49). These findings suggest that a larger cortical area was dedicated to representing the sensations from the fingers of the musicians, owing to their altered but otherwise normal sensory experience. Interestingly, these musicians typically began training early in life, and the size of the effect (the enhancement in the response) correlated with the age at which they began their musical training.

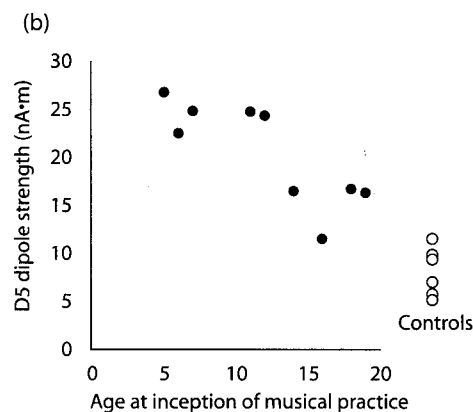
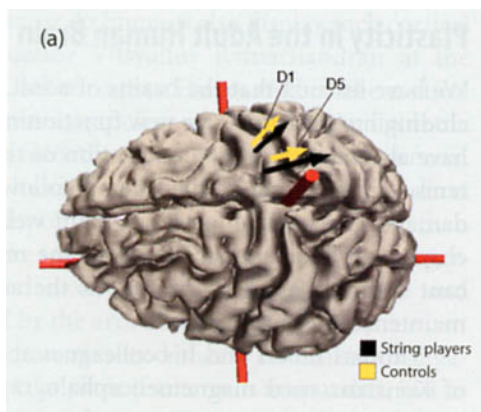
Leslie Ungerleider and her colleagues (Karni et al., 1995) at the National Institute of Mental Health have also researched plasticity in the adult motor system. They asked a group of volunteers to perform a simple motor task with one hand; the task required the subjects to touch finger to thumb in a particular sequence. They had to perform the task only a few minutes each day, but their accuracy and speed of finger–thumb touching improved with this practice. Using functional magnetic resonance imaging (fMRI), which is described in Chapter 4, the scientists measured the size of activity-related changes in blood flow in the motor cortex for the prac-

ticed sequences and untrained sequences. Figure 3.50 shows the results: There were greater changes in blood flow in the corresponding motor cortex for trained than for untrained sequences after a few weeks. Indeed, recent evidence indicates that cortical reorganization can occur after just 15 to 30 minutes of practice (Classen et al., 1998).

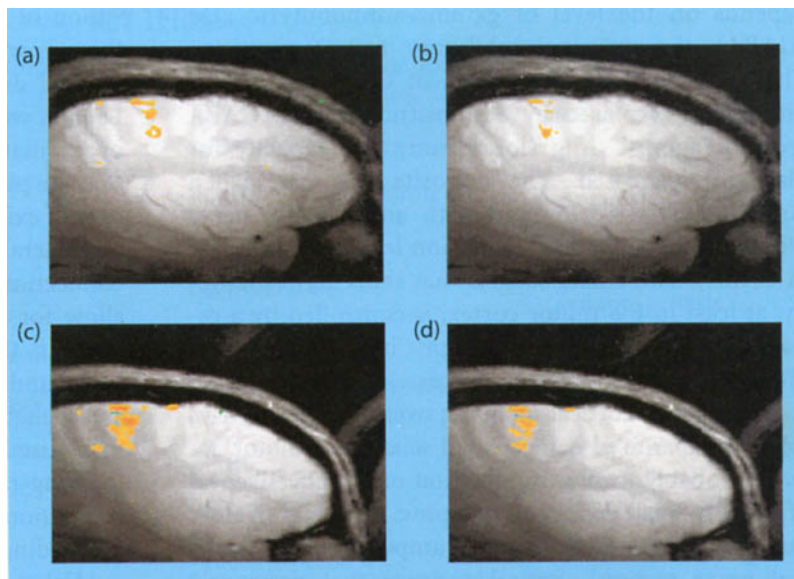
Further evidence that adult brains show plasticity comes from the lab of Norihiro Sadato at the National Institutes of Health. Sadato and his colleagues (1996) used PET to measure blood flow in the visual cortex during a tactile discrimination task in both blind and sighted subjects. They found that, in the blind, blood flow increased in primary and secondary visual cortex, which normally responds only to visual stimulation, whereas it decreased in sighted subjects during the task.

More recently, Alvaro Pascual-Leone and his colleagues at Harvard Medical School (Kauffman et al., 2002) have studied the cortical plasticity effects of extended blindfolding of *sighted* volunteers. The study included four groups of participants. Two groups were continuously blindfolded for 5 days, during which one group received intensive Braille training and the other did not. Matched control groups were not blindfolded. Regardless of whether the blindfolded subjects were

**Figure 3.49** Changes in the cortical representation of the human fingers in musicians who play string instruments. **(a)** Top view of a three-dimensional human brain reconstructed from MRI; anterior is to the left. The arrows over the right hemisphere indicate the calculated locations of neural activity recorded using MEG for the thumb (D1) and fifth finger (D5). The black arrows represent the thumb and fifth finger for musicians; the yellow arrows represent nonmusicians. The arrow size shows the strength of the responses (to stimulation of the thumb and finger). Musicians show larger responses and a larger area of cortical representation for the thumb and fifth finger (distance between arrows). **(b)** The size of the cortical response, plotted as a function of the age at which the musicians begin training. Responses were larger for those who began training prior to the age of 12 years; controls are shown at the lower right of the graph.



**Figure 3.50** Changes in the size of cortical activation of hand movements with training. **(a)** A sagittal section through the right hemisphere of a representative subject shows greater activation (larger area activated—yellow-orange) for motor sequences that were repeated over many sessions in comparison to motor-evoked activity for untrained sequential movements **(b)**. These activations were in M1, the primary motor cortex. The increased activation for trained movements **(c)** in comparison to untrained movements **(d)** lasted up to 8 weeks, even when no training ensued on the task in the interim.



trained, after only 5 days of visual deprivation they could discriminate Braille letters better than nonblindfolded subjects could. This finding implies that, once deprived of normal input, the adult visual system can become engaged in tactile analysis in a very short period of time. Furthermore, fMRI of these subjects revealed activation in the visual cortex during tactile stimulation of the right or left fingertips using a brush (to reduce the likelihood of visual imagery) during the last day of the study (the 5th day). Interestingly, just 20 hours after the blindfold was removed (on day 6) the activation in visual cortex during tactile stimulation disappeared.

Furthermore, transcranial magnetic stimulation (TMS) of the occipital cortex disrupted tactile discrimination abilities during the last day of blindfolding, but not after the blindfold was removed on the 6th day, suggesting a functional role of the visual cortex activation in tactile discrimination during blindfolding. Similarly, auditory stimulation was shown to activate the visual cortex in blindfolded subjects: Left-lateralized activations of the medial occipital lobe and the posterior extension of the superior temporal lobe were found in the blindfolded population during tone and phoneme matching tasks.

These data argue that, in the normal brain, training can induce relatively rapid changes in cortical organization that reflect the plastic ability of the nervous system to acquire and retain new information and skills. The possibility that someday such neural reorganization

could serve a clinically beneficial role is enticing. However, before that is possible, neuroscientists must unravel the mechanisms underlying such plasticity.

### Mechanisms of Cortical Plasticity

Most of the evidence for the mechanisms of cortical plasticity comes from animal studies (Steven & Blake, 2005). The results suggest a cascade of effects, operating across different timescales. In both humans and other animals, changes in cortical mapping can be detected essentially immediately after the change in sensory input or motor activity. But additional components of the plasticity take longer to appear. There appear to be at least three distinct mechanisms: two that account for short-term changes, and a separate mechanism for very long-term effects.

Rapid changes probably reflect both the unveiling of weak connections that already exist in the cortex, through both release from inhibition and changes in the efficacy of synapses. Longer term plasticity may result from the growth of new synapses and/or axons.

Immediate effects (e.g., as a result of amputation) are likely to be due to a sudden reduction in the level of inhibitory synaptic activity in the cortex, which normally suppresses weak inputs onto cortical cells from regions of the receptor surface beyond their classical receptive fields. Ulf Ziemann and his colleagues (2001) at the Johann Wolfgang Goethe-University of Frankfurt report that reorganization in the motor cortex

depends on the level of gamma-aminobutyric acid (GABA), the principal inhibitory neurotransmitter. They showed that, as the level of GABA-ergic inhibition was increased by administration of a GABA receptor agonist drug (lorazepam), the capacity for plasticity decreased. The opposite was true when GABA levels were lowered with an ischemic nerve block in the hand (deafferentation leads to a decrease in GABA). These data suggest that short-term plasticity, at least in the motor cortex, is controlled by a release of tonic inhibition on synaptic input (thalamic or intracortical) from remote sources.

Changes in cortical mapping over a period of days following increased or decreased sensory or motor activity probably involve modulation of the effectiveness of initially weak excitatory synapses. After loss of normal sensory input (e.g., through amputation or peripheral nerve section) cortical neurons that previously responded to that input might undergo "denervation hypersensitivity"—up-regulation of the strength of their responses to any remaining weak excitatory input. But remapping as a result of more subtle changes in activity (e.g., through motor or sensory learning) might well depend on regulated changes in synaptic efficacy similar to the forms of long-term potentiation and depression in the hippocampus that are thought to underlie the formation of spatial and episodic memories (see Chapter 8). Finally, some evidence in animals suggests that the growth of intracortical axonal connections and even sprouting of new axons might contribute to these very slow changes.

Less is known about the basis of changes in activity beyond individual cortical areas, such as the tactile acti-

vation of visual areas in the blind. It is unlikely that there is wholesale growth of new long-range cortico-cortical association connections, given that Pascual-Leone's work shows that these changes can take place over a matter of days. More plausible is the hypothesis that the plasticity occurs because of changes in the efficacy of existing circuitry, but there is little evidence and no general agreement about which particular form of connections might be involved. A great many pathways allow for feedback from "higher" to "lower" sensory areas in the cortex, and this extensive network may come under the control of inputs from other sensory areas, enabling them to activate regions of cortex normally used for a different sensory system. Alternatively, the long-range influences might be mediated through facilitation of multiple, serial connections, or even of descending and ascending loops via the thalamus.

Helen Neville at the University of Oregon and her colleagues (Neville & Lawson, 1987) have pointed out that some of the areas that show unusual responses after sensory loss (e.g., in the blind and deaf) are normally involved in multimodal sensory processing (including higher visual cortical areas in the temporal lobe and the inferior parietal lobe, among others). Since multimodal areas already have input from several senses, it is not so surprising that loss of input from one sense should lead to the enhancement of response to a remaining sensory input, perhaps through modulation of the strength of synapses from association connections.

This is a hot topic in neuroscience research, and we hope that definitive answers about the mechanisms of each form of cortical plasticity will be revealed in the near future.

## SUMMARY

The nervous system is composed of neurons and their supportive counterparts, the glial cells. The neuron is the elementary unit of structure and function within the brain and spinal cord of the central nervous system and the peripheral nervous system, which includes the autonomic nervous system. These elementary units and their interconnections can be viewed directly by use of a variety of gross dissection methods, and analyzed in detail with microanatomical methods. Connections can be traced with special substances that are taken up by neurons and transported down their axons either in an anterograde (from soma to axon terminals) or a retrograde (from terminals to soma) direction.

Neuronal circuits are organized to form highly specific interconnections between groups of neurons in

subdivisions of the central nervous system. Different neuronal groups have different functional roles. The functions might be localized within discrete regions that contain a few or many subdivisions, identifiable either anatomically or functionally, but usually by a combination of both approaches. Brain areas are also interconnected to form higher level circuits or systems that are involved in complex behaviors such as motor control, visual perception, or cognitive processes such as memory, language, and attention. Neurodevelopment begins at an early stage in fetal growth and continues through birth and adolescence. New research also suggests that new neurons and new synapses form throughout life, allowing, at least in part, for cortical plasticity.



## KEY TERMS

amygdala	cytoarchitectonic map	neuronal determination and differentiation	radial glial cell
association cortex	dura mater	neuronal migration	somatotopy
autonomic nervous system	ectoderm	neuronal proliferation	sulci
basal ganglia	frontal lobe	nucleus	Sylvian fissure
brainstem	gray matter	occipital lobe	synapse elimination
central nervous system (CNS)	gyri	parietal lobe	synaptogenesis
cerebellum	hippocampus	peripheral nervous system (PNS)	temporal lobe
cerebral cortex	hypothalamus	plastic	thalamus
commissure	limbic system	pons	topography
corpus callosum	medulla	precursor cells	tract
corticogenesis	midbrain	prefrontal cortex	white matter
	neocortex		

## TAKE-HOME MESSAGES

### General

- Gross neuroanatomy encompasses the large brain structures that can be viewed by the naked eye; fine neuroanatomy, or microscopic neuroanatomy, has to do with the organization of the brain at the cellular or subcellular level.

### Neuroanatomy

- The central nervous system consists of the brain and spinal cord. The peripheral nervous system consists of all nerves outside of the central nervous system.
- The lobes of the brain include the frontal, parietal, temporal, occipital (and occasionally limbic) lobes. The frontal lobe is for planning, cognitive control, and execution of movements. The parietal lobe receives sensory input about touch, pain, temperature, and limb position, and is involved in coding space and coordinating actions. The temporal lobe contains auditory, visual, and multimodal processing areas. The occipital lobe processes visual information. The limbic lobe is involved in emotional processing, learning, and memory.
- Gyri are the protruding areas seen on the surface of the cortex; sulci, or fissures, are the enfolded regions of cortex.
- Gray matter is formed by the cell bodies in the brain; white matter is formed by the axons.
- White matter forms tracts that connect various regions of the brain. Tracts are referred to by source

and then by target. For example, the corticospinal tract goes from the cortex to the spinal cord.

- Retrograde tracers are injected at the axon terminal and proceed up the axon to label the cell body. Anterograde tracers are injected at the cell body and travel down the axon to label the axon and the axon terminals.
- The corpus callosum is the largest interhemispheric (commissural) white matter tract in the brain.
- Brodmann divided the brain into distinct regions based on the underlying cytoarchitectonics.
- Cerebral cortex can be subdivided into major regions that differ in the degree of complexity of the neuronal layering (e.g., neocortex, allocortex, and paleocortex).
- The basal ganglia are involved in movement processing.
- The hippocampus is involved in learning and memory.
- The thalamus is the relay station for almost all sensory information. Association cortex is neocortex that is neither sensory nor motor in function.
- The hypothalamus is important for the autonomic nervous system and endocrine system. It controls functions necessary for the maintenance of homeostasis. It is also involved in emotional processing and in the control of the pituitary gland.

- The brainstem includes the midbrain, pons, and medulla. Nuclei of the brainstem control respiration, sleep, and wakefulness.
- The cerebellum integrates information about the body and motor commands and modifies motor outflow to effect smooth, coordinated movements.
- The spinal cord conducts the final motor signals to the muscles, and it relays sensory information from the body's peripheral receptors to the brain.
- The autonomic nervous system is involved in controlling the action of smooth muscles, the heart, and various glands. It includes the sympathetic and parasympathetic systems.
- The sympathetic system uses the neurotransmitter norepinephrine. This system increases heart rate, diverts blood from the digestive tract to the somatic musculature, and prepares the body for fight-or-flight responses by stimulating the adrenal glands.
- The parasympathetic system uses acetylcholine as a neurotransmitter. It is responsible for decreasing heart rate and stimulating digestion.

#### *Neurodevelopment*

- The nervous system develops from the ectoderm, which forms a neural plate. The neural plate becomes the neural groove and eventually the neural tube.
- Neuronal proliferation is the process of cell division in the developing embryo and fetus. It is responsible for populating the nervous system with neurons.
- Neurons and glial cells are formed from precursor cells. After mitosis these cells migrate along the radial glial cells to the developing cortex.

- The key to the type of cell that will be made (e.g., a stellate or pyramidal cell) appears to be the time at which the cell is born (genesis) rather than the time at which it begins to migrate.
- The radial unit hypothesis states that the columnar organization in the adult cortex is derived during development from cells that divide in the ventricular region.

#### *Neurogenesis and Plasticity*

- A belief strongly held by the general public (and, until recently, by most neuroscientists) was that the adult brain produces no new neurons. We now know that that is not the case and that new neurons form throughout life in certain brain regions.
- Synaptogenesis is the birth of new synapses; neurogenesis is the birth of new neurons.
- The adult brain is plastic—that is, able to change or remap its function. The topographic map of the sensory cortex, for instance, will remap to reflect changes in sensory experience (e.g., increased use of the fingers of the left hand as in violin playing, or increased use of part of the body because of the loss of a limb). And the visual cortex is able to remap to process information about touch and audition after sensory deprivation (e.g., the onset of blindness).
- The mechanisms that underlie cortical plasticity are not entirely understood but might include one or both of the following: (a) unveiling of weak connections that already exist in the cortex through the release from inhibition and/or changes in the efficacy of the synapses; (b) growth of new neurons or synapses.

### THOUGHT QUESTIONS

1. What is the evolutionary significance of the different types of cortex (e.g., neocortex versus allocortex)?
2. What is the functional advantage of organizing cortex as a sheet of neurons, rather than as groups of nuclei such as those found in subcortical structures?
3. What region of the cerebral cortex has increased in size the most across species during evolution? What does this brain region subservise in humans that is absent or reduced in animals?
4. Why are almost all sensory inputs routed through the thalamus on the way to cortex? Would it not be faster and therefore more efficient to project these inputs directly from sensory receptors to the primary sensory cortex?
5. Although the brainstem is relatively small in comparison with the forebrain, it contains some essential structures. Select one and describe how its anatomical organization supports its role in brain function.
6. Once the human brain is past the critical period in development and is fully developed, damage has less impact on its organization. But how would a person losing a limb in an accident in adulthood feel the missing limb, and why might this feeling be triggered by stimulation of the remaining body parts?
7. Expert violinists may have larger regions of the brain dedicated to somatosensory processing in the hand and finger region of the brain. Are these individuals born with more cortex dedicated to somatomotor processing? What evidence in animals helps resolve the study of this form of plasticity?

**SUGGESTED READING**

- MESULAM, M.-M. (2000). Behavioral neuroanatomy: Large-scale networks, association cortex, frontal syndromes, the limbic system, and hemispheric specialization. In M.-M. Mesulam (Ed.), *Principals of behavioral and cognitive neurology* (pp. 1–34). New York: Oxford University Press.
- SHAW, P., GREENSTEIN, D., LERCH, J., CLASEN, L., LENROOT, R., GOGTAY, N., ET AL. (2006). Intellectual ability and cortical development in children and adolescents. *Nature*, *440*, 676–679.
- SHEPHERD, G. M. (1988). *Neurobiology* (2nd ed.). New York: Oxford University Press.
- SHORS, T. J. (2004). Memory traces of trace memories: Neurogenesis, synaptogenesis and awareness. *Trends in Neurosciences*, *27*, 250–256.
- STEVEN, M. S., & BLAKEMORE, C. (2004). Cortical plasticity in the adult human brain. In M. Gazzaniga (Ed.), *The cognitive neurosciences* (3rd ed., pp. 1243–1255). Cambridge, MA: MIT Press.